

# Mediastinoscopy vs Endosonography for Mediastinal Nodal Staging of Lung Cancer

## A Randomized Trial

Jouke T. Annema, MD, PhD

Jan P. van Meerbeeck, MD, PhD

Robert C. Rintoul, FRCP, PhD

Christophe Dooms, MD, PhD

Ellen Deschepper, PhD

Olaf M. Dekkers, MA, MD, PhD

Paul De Leyn, MD, PhD

Jerry Braun, MD

Nicholas R. Carroll, FRCP, FRCR

Marleen Praet, MD, PhD

Frederick de Ryck, MD

Johan Vansteenkiste, MD, PhD

Frank Vermassen, MD, PhD

Michel I. Versteegh, MD

Maud Veselić, MD

Andrew G. Nicholson, FRCP, DM

Klaus F. Rabe, MD, PhD

Kurt G. Tournoy, MD, PhD

LUNG CANCER IS THE MOST COMMONLY diagnosed cancer worldwide (1.35 million/year) and also the most frequent cause of cancer death (1.18 million/year).<sup>1</sup> Clinical staging of lung cancer is an integral part of patient care because it directs therapy and has prognostic value. Imaging with computed tomography (CT) is valuable for assessing the primary tumor (T-stage) while fluorodeoxyglucose positron emission tomography (PET) is valuable for detecting metastases. In cases where the primary tumor is resectable and in the ab-

**For editorial comment see p 2296.**

**Context** Mediastinal nodal staging is recommended for patients with resectable non-small cell lung cancer (NSCLC). Surgical staging has limitations, which results in the performance of unnecessary thoracotomies. Current guidelines acknowledge minimally invasive endosonography followed by surgical staging (if no nodal metastases are found by endosonography) as an alternative to immediate surgical staging.

**Objective** To compare the 2 recommended lung cancer staging strategies.

**Design, Setting, and Patients** Randomized controlled multicenter trial (Ghent, Leiden, Leuven, Papworth) conducted between February 2007 and April 2009 in 241 patients with resectable (suspected) NSCLC in whom mediastinal staging was indicated based on computed or positron emission tomography.

**Intervention** Either surgical staging or endosonography (combined transesophageal and endobronchial ultrasound [EUS-FNA and EBUS-TBNA]) followed by surgical staging in case no nodal metastases were found at endosonography. Thoracotomy with lymph node dissection was performed when there was no evidence of mediastinal tumor spread.

**Main Outcome Measures** The primary outcome was sensitivity for mediastinal nodal (N2/N3) metastases. The reference standard was surgical pathological staging. Secondary outcomes were rates of unnecessary thoracotomy and complications.

**Results** Two hundred forty-one patients were randomized, 118 to surgical staging and 123 to endosonography, of whom 65 also underwent surgical staging. Nodal metastases were found in 41 patients (35%; 95% confidence interval [CI], 27%-44%) by surgical staging vs 56 patients (46%; 95% CI, 37%-54%) by endosonography ( $P = .11$ ) and in 62 patients (50%; 95% CI, 42%-59%) by endosonography followed by surgical staging ( $P = .02$ ). This corresponded to sensitivities of 79% (41/52; 95% CI, 66%-88%) vs 85% (56/66; 95% CI, 74%-92%) ( $P = .47$ ) and 94% (62/66; 95% CI, 85%-98%) ( $P = .02$ ). Thoracotomy was unnecessary in 21 patients (18%; 95% CI, 12%-26%) in the mediastinoscopy group vs 9 (7%; 95% CI, 4%-13%) in the endosonography group ( $P = .02$ ). The complication rate was similar in both groups.

**Conclusions** Among patients with (suspected) NSCLC, a staging strategy combining endosonography and surgical staging compared with surgical staging alone resulted in greater sensitivity for mediastinal nodal metastases and fewer unnecessary thoracotomies.

**Trial Registration** clinicaltrials.gov Identifier: NCT00432640

JAMA. 2010;304(20):2245-2252

www.jama.com

**Author Affiliations:** Departments of Pulmonology (Drs Annema and Rabe); Clinical Epidemiology, Endocrinology, and Metabolic Diseases (Dr Dekkers); Cardio-Thoracic Surgery (Drs Braun and Versteegh); and Pathology (Dr Veselić), Leiden University Medical Center, Leiden, the Netherlands; Lung Oncology Network (Drs van Meerbeeck, Praet, de Ryck, Vermassen, and Tournoy) and Department of Biostatistics (Dr Deschepper), Ghent University Hospital, Ghent, Belgium; Department of Thoracic Oncology, Papworth Hospital, Cambridge, United Kingdom (Drs Rintoul and

Carroll); Departments of Pulmonology (Drs Dooms and Vansteenkiste) and Surgery (Dr De Leyn), Leuven University Hospitals, Leuven, Belgium; Department of Histopathology, Royal Brompton Hospital, Harefield Hospital, and National Heart and Lung Division, Imperial College School of Medicine, London, United Kingdom (Dr Nicholson).

**Corresponding Author:** Jouke T. Annema, MD, PhD, Department of Pulmonology, C3-P, Leiden University Medical Center, Albinusdreef 2, 2333 ZA Leiden, the Netherlands (j.t.annema@lumc.nl).

sence of distant metastases, mediastinal nodal involvement (N-stage) directs treatment. Surgical resection of the tumor is the treatment of choice in the absence of mediastinal nodal metastases,<sup>2</sup> whereas combined modality treatment is indicated for patients with mediastinal nodal metastases.<sup>3</sup>

To detect mediastinal metastases, patients are routinely investigated with CT and fluorodeoxyglucose PET, followed by mediastinal tissue staging for enlarged or PET-positive intrathoracic nodes,<sup>4,5</sup> as imaging alone is inaccurate. Mediastinal tissue staging is classically performed by mediastinoscopy, a surgical diagnostic procedure with a sensitivity of approximately 78%.<sup>5</sup> Undetected mediastinal metastases are a major cause of unnecessary thoracotomies, occurring in 28% of patients.<sup>6</sup> Unnecessary thoracotomies result in suboptimal treatment, significantly impaired functional health status, and avoidable mortality.<sup>7</sup>

Mediastinal lymph nodes can also be sampled under real-time ultrasound control from either the esophagus (transesophageal ultrasound-guided fine-needle aspiration [EUS-FNA])<sup>8</sup> or the airways (endobronchial ultrasound-guided transbronchial needle aspiration [EBUS-TBNA]).<sup>9</sup> Combined EUS and EBUS can reach almost all mediastinal nodal stations with a reported sensitivity of 93%.<sup>10</sup> Current lung cancer staging guidelines acknowledge endosonography as a minimally invasive alternative to surgical staging to detect nodal disease,<sup>4,5</sup> reducing the need for surgical staging in up to two-thirds of patients.<sup>11,12</sup> At present it is not known whether initial mediastinal tissue staging of lung cancer by endosonography improves the detection of nodal metastases and reduces the rate of unnecessary thoracotomies.

This study was originally planned to examine the hypothesis that minimally invasive combined endoscopic procedures are as good as or even better than surgical staging (mediastinoscopy) for the evaluation of mediastinal lymph nodes in patients with lung cancer. However, since international

guidelines regard surgical staging as the gold standard and currently state that endosonography should be followed by surgical staging if no metastases are found by endosonography, we incorporated this diagnostic sequence into the protocol. Therefore, the primary analysis compared surgical staging alone vs endosonography followed by surgical staging, thereby allowing evaluation between these 2 diagnostic strategies. In addition, we compared surgical staging against endosonography alone.

## METHODS

Patients with potentially resectable non-small cell lung cancer (NSCLC) were eligible if there was an indication for mediastinal nodal sampling according to current guidelines<sup>4,5</sup> (mediastinal nodes with short axis  $\geq 10$  mm or PET-positive mediastinal or hilar nodes or centrally located lung tumor). Patients with proven distant metastasis, irresectable disease (as judged by the thoracic surgeon on the available imaging), or small peripheral lung tumors without evidence of enlarged or PET-positive intrathoracic nodes were not considered for eligibility. Patients also had to be 18 years or older and able to undergo surgical resection of the lung tumor. Prior diagnostic evaluation included conventional workup (medical history, physical examination, laboratory tests, and bronchoscopy), CT, and integrated whole-body PET-CT. Exclusion criteria were concurrent malignancy; technical contraindication to EUS (eg, esophageal stenosis), EBUS, or surgical staging (eg, prior mediastinoscopy, current tracheostomy); pregnancy; or inability to consent.

Candidates for study participation were identified at the weekly multidisciplinary lung oncology meeting of the participating centers and provided written informed consent. This investigator-initiated trial was approved by the ethical committees of the 4 participating hospitals (Leiden University Medical Center, the Netherlands; the University Hospitals of Ghent and Leuven in Belgium; and Papworth Hospital,

United Kingdom) and registered as ASTER (Assessment of Surgical Staging vs Endosonographic Ultrasound in Lung Cancer: a Randomized Clinical Trial).

## Study Design

Patients were randomly assigned (1:1) to either surgical staging alone (surgical staging group, current standard of care) or endosonography (combined EUS-FNA and EBUS-TBNA) followed by surgical staging if no nodal metastases were found at endosonography (endosonography group, novel alternative staging strategy). In the event of pathological proof of mediastinal (N2/N3) metastases or evidence of mediastinal tumor invasion implying irresectability (T4), patients were classified as having locally advanced disease (stage IIIA/B) and were referred for multimodality therapy. For patients without evidence of mediastinal metastases following surgical staging in either study group, a thoracotomy with complete lymph node dissection was performed. Per protocol, study inclusion, preliminary findings, and complications were evaluated 1 year after start of the study.

## Endosonography

Endosonography of the mediastinum was performed with patients under moderate sedation as previously described.<sup>13,14</sup> EUS-FNA was performed initially (Pentax 34UX/38UX; Pentax, Tokyo, Japan, or Olympus GF-UCT140-AL5; Olympus, Tokyo) followed by EBUS-TBNA (Olympus BF-UC160F-OL). A systematic examination of left and right paratracheal, subcarinal, and paraesophageal mediastinal nodes was performed. Nodes that were suspicious on CT, PET, or ultrasound imaging<sup>15</sup> were sampled under real-time ultrasound guidance with 22-gauge needles and labeled<sup>16</sup> according to the Mountain-Dresler map.<sup>17</sup> When the primary lung tumor was visible by endosonography, the presence or absence of direct mediastinal tumor invasion (T4) was recorded. The cytology preparations were analyzed using

either May-Grünwald-Giemsa or Papanicolaou stains dependent on local practice, with additional preparation of cell blocks for histological analysis when appropriate. At completion of the study, all EUS and EBUS samples were re-evaluated by an independent reference pathologist (A.G.N.) to assess interobserver agreement.

### Surgical Staging and Thoracotomy

Surgical staging was performed by mediastinoscopy according to current guidelines.<sup>4</sup> A systematic assessment of left and right high and lower paratracheal and subcarinal nodes was performed. If deemed necessary, a left parasternal mediastinotomy or video-assisted thoracoscopy was performed in addition to mediastinoscopy. The nodal samples taken were labeled<sup>17</sup> and sent for pathological examination. In cases where the primary tumor was visible, the presence or absence of mediastinal invasion (T4) was noted.

Thoracotomy was performed according to current guidelines<sup>18</sup> in the absence of mediastinal nodal metastasis or direct mediastinal tumor invasion following surgical staging. At the time of lung resection, a systematic lymph node dissection was performed (at least 3 mediastinal stations, including the subcarinal station) according to current guidelines.<sup>18</sup> All hilar and intrapulmonary (N1) lymph nodes were counted as a single station. Histological examination of the resected nodes and resection specimen and pTpN classification was performed according to current guidelines.<sup>19</sup>

### End Points

The primary end point was sensitivity for detection of mediastinal nodal (N2/N3) metastases by either staging strategy. Sensitivity was defined as the proportion of patients with N2/N3 disease for whom the diagnostic test was positive. Thoracotomy with nodal dissection was considered the reference standard in both study groups for cases without N2/N3 involvement after mediastinal staging. Because reported false-positive EUS/EBUS findings are rare,<sup>13,20</sup>

it was decided at the time of study design, in conjunction with the ethics committees, that positive EUS/EBUS results would not be verified by surgical staging because this would lead to inappropriate surgery in virtually all of these patients.

Secondary end points were as follows: (1) rate of unnecessary thoracotomies defined as either exploratory thoracotomy, unexpected presence of mediastinal nodal metastases (pN2/N3) or tumor invasion of the mediastinum at thoracotomy (pT4), pM1, thoracotomy for SCLC or benign disease (other than carcinoid or hamartoma), or death within 30 days after surgery; (2) rate of complications due to preoperative staging procedures, defined as persistent (>6 months) hoarseness, pneumothorax, mediastinitis, major bleeding, and necessary conversion to thoracotomy; (3) detection rate of locally advanced disease, defined as mediastinal nodal metastases or tumor invasion (cT4 or cN2/N3); (4) rate of avoided mediastinoscopies due to endosonography findings; (5) detection rate of nodal metastases by endosonography alone vs surgical staging; and (6) interobserver agreement of EUS/EBUS cytology.

### Statistical Analysis

For the primary analysis, sensitivity and negative predictive value (NPV) regarding mediastinal nodal status were calculated on an intention-to-treat basis for all randomized patients. For patients with a missing reference standard, a multiple imputation procedure was used to obtain 100 000 samples from the most likely value for the missing data. Sampling was based on a binomial distribution with estimated probability for positive mediastinal nodes. Median values of simulated distributions are reported. In a secondary (complete case) analysis, sensitivity and NPV were calculated on those patients for whom complete information on mediastinal nodal status was available. Cases for which surgical-pathological verification of negative findings on endosonography or surgical staging were missing were excluded for the aim of this

specific analysis. In a third analysis, sensitivity and NPV of surgical staging vs endosonography alone was performed. For this analysis, we also used multiple imputations for the missing data.

A sample size of at least 186 patients was initially calculated to demonstrate a 20% increase in the sensitivity to detect mediastinal nodal metastases (N2/N3) with endosonography followed by surgical staging vs surgical staging alone, assuming a prevalence of mediastinal nodal metastases of 70% and a dropout rate of 5% (power 80%, type I error  $P < .05$ , 2-sided testing). However, during a prespecified interim monitoring of the study, the prevalence of mediastinal nodal metastases was found to be 55%, and therefore the sample size was increased to 240 patients. No end point analysis was performed at this time. Randomization of patients between the 2 groups was stratified per hospital using a web-based program.

A  $\kappa$  value was calculated to assess the interobserver agreement of both the EUS and the EBUS cytology samples. Fisher exact tests were used for the analysis of categorical data and to compare sensitivity and NPV between study groups. Independent  $t$  tests were used to compare groups of continuous, normally distributed variables. Statistical analyses were performed using SPSS 17.0 (SPSS Inc, Chicago, Illinois) and R version 2.10.0 (R Foundation for Statistical Computing, <http://www.r-project.org/>). A  $P$  value of .05 or less was considered statistically significant. All tests performed were 2-sided. Two-sided 95% Wilson score confidence intervals (CIs) for single proportions were calculated using the epiR library (version 0.9-19).

## RESULTS

Between February 2007 and April 2009, 357 consecutive patients with resectable (suspected) NSCLC were assessed for eligibility. Two hundred forty-one patients were randomized, 118 to surgical staging and 123 to endosonography followed by surgical stag-

ing (FIGURE). Both groups were well balanced for all major clinical characteristics (TABLE 1).

### Surgical Staging Alone

Surgical staging was performed in 117 patients because a distant metastasis was found in 1 patient before the surgical staging procedure. One hundred sixteen patients underwent cervical mediastinoscopy, which was combined with a parasternal mediastinotomy in 3 and a thoracoscopy in 2 patients. One patient underwent a thoracoscopy only. A median of 4 mediastinal nodal stations (range, 0-5) were sampled at surgical staging. Mediastinal metastases were found in 41 of 118 patients (35%; 95% CI, 27%-44%). In 4 patients (1 without nodal metastases), direct mediastinal invasion by the lung tumor was found. In the 75 patients without locally advanced disease, thoracotomy was performed in 70 patients, showing nodal metastases in 10 (of whom 2 also had mediastinal tumor invasion) and mediastinal invasion alone in 6 patients (Figure).

### Endosonography Followed by Surgical Staging

Endosonography was performed in 123 patients and detected mediastinal nodal metastases in 56 of 123 patients (46%; 95% CI, 37%-54%;  $P=.11$ ). In 5 patients (2 without nodal metastases), it was obvious on endosonographic imaging that the primary lung tumor invaded the mediastinum (cT4). Surgical staging was avoided due to endosonography findings in 58 of 123 patients (47%; 95% CI, 39%-56%). Sixty-five patients without evidence of mediastinal nodal metastases or mediastinal tumor invasion underwent surgical staging, showing nodal metastases in 6 additional patients. These missed mediastinal metastases (in 2 cases only micrometastases) were located in stations 4R (n=3), 5 (n=1), 6 (n=1), and 7 (n=1). The metastases in stations 5 and 6 were out of reach for endosonography. Fifty-eight patients without evidence of mediastinal nodal metastases after endosonog-

raphy and surgical staging underwent thoracotomy with nodal dissection. As a result, nodal metastases were found in a further 4 patients, and 2 others were found to have mediastinal tumor invasion (Figure). At endosonography and surgical staging, a median of 3 different mediastinal nodal stations (range, 0-7) were sampled. The interobserver agreement in relation to cytological diagnosis of samples obtained with endosonography was high:  $\kappa=0.97$  (95% CI, 0.92-1.00).

### Final Diagnoses and False-Negative Findings

The final diagnoses of the 241 patients were NSCLC (n=229; 95%; 95% CI, 91%-97%); SCLC (n=5; 2%; 95% CI, 1%-5%); other diagnoses, such as sarcoidosis (n=5; 2%; 95% CI, 1%-5%); and unknown (n=2; 1%; 95% CI, 1%-3%) (Table 1). At thoracotomy, a median of 5 lymph node stations (range, 0-10) were assessed in both study groups. At preoperative staging, nodal metastases were missed in 10 patients in the surgical staging group (stations 4L, 4R, 5, and 7) and in 4 patients in the endosonography group (stations 3A, 4L, 4R, 5, 8L, and 8R). For 8 patients (7%; 95% CI, 3%-13%) from the surgical staging group and 3 patients (2%; 95% CI, 1%-7%) from endosonography, there was no surgical verification of nodal negative findings at staging. The prevalence of mediastinal nodal metastases was 49% overall (118/241; 95% CI, 43%-56%) and similar in the surgical staging and endosonography groups: 44% (52/118; 95% CI, 35%-53%) and 54% (66/123; 95% CI, 45%-62%), respectively ( $P=.16$ ). In this analysis, multiple imputation was used to assign values to missing data for mediastinal nodal status (n=8 for the surgical staging group and n=3 for the endosonography group), resulting in 1 additional patient with a nodal metastasis in the surgical group and no change in the endosonography group.

### Primary End Point

According to intention-to-treat analysis for detecting mediastinal nodal me-

tastases by surgical staging (n=118) vs endosonography followed by surgical staging (n=123), the sensitivity for surgical staging was 79% (41/52; 95% CI, 66%-88%) and, for endosonography plus surgical staging, 94% (62/66; 95% CI, 85%-98%) ( $P=.02$ ). The negative predictive value (NPV) for surgical staging was 86% (66/77; 95% CI, 76%-92%) and, for endosonography and surgical staging, 93% (57/61; 95% CI, 84%-97%) ( $P=.18$ ) (TABLE 2).

In the sensitivity analysis on all patients with information on mediastinal nodal status (complete cases scenario, n=110 for surgical staging and n=120 for endosonography plus surgical staging), the sensitivity of surgical staging was 80% (41/51; 95% CI, 68%-89%) vs 94% (62/66; 95% CI, 85%-98%) for endosonography ( $P=.04$ ), with corresponding NPVs of 86% (59/69; 95% CI, 75%-92%) and 93% (54/58; 95% CI, 78%-94%) ( $P=.26$ ), respectively.

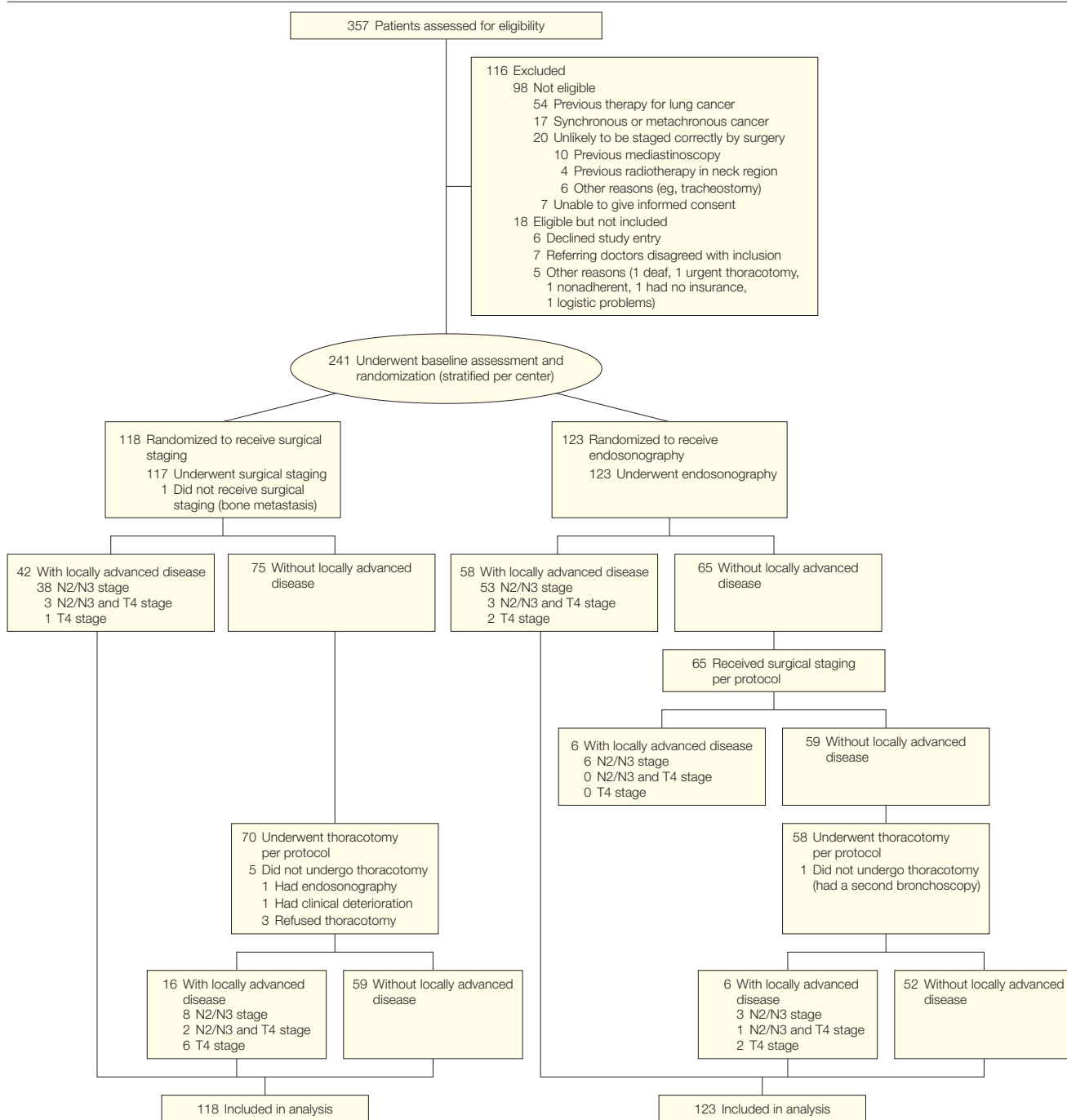
### Nodal Metastases or Tumor Invasion

Mediastinal nodal (N2/N3) metastases were found in 41 of 118 patients (35%, 95% CI, 27%-44%) by surgical staging vs 62 of 123 patients (50%; 95% CI, 42%-59%) by the combined approach ( $P=.02$ ). Additionally, tumor invasion (T4) was identified in 1 patient in the surgical staging group and 2 patients in the endosonography group (Figure). Thus, in the surgical group, 42 of 118 patients (36%; 95% CI, 28%-45%) were found to have locally advanced disease (nodal metastases and/or unforeseen direct mediastinal invasion) vs 64 of 123 patients (52%; 95% CI, 43%-61%) in the endosonography group ( $P=.01$ ).

### Secondary End Points

The number of unnecessary thoracotomies was 21 of 118 (18%; 95% CI, 12%-26%) in the surgical staging vs 9 of 123 (7%; 95% CI, 4%-13%) in the endosonography group ( $P=.02$ ) (TABLE 3). There was no difference in the complication rate between the 2 groups, 7 of 118 (6%; 95% CI, 3%-12%) in the

**Figure.** Enrollment and Randomization of Study Patients



N2/N3 indicates patients with locally advanced disease due to malignant unilateral (N2) or contralateral (N3) mediastinal lymph nodes. T4 indicates patients with locally advanced disease based on direct mediastinal tumor invasion. The patients with T4 because of multiple nodules in the same lobe are not shown here. In the patients without locally advanced disease, there was no evidence of either mediastinal nodal invasion or mediastinal tumor invasion. For 11 patients, there was no verification of the mediastinal nodal status (8 patients in the surgical staging group and 3 in the endosonography group). Nine of these patients did not have a thoracotomy. Two patients had a thoracotomy, but no nodal biopsies were taken. For 3 patients, there was evidence of presence of metastatic nodules in a different ipsilateral lobe (pM1) during thoracotomy (see Table 3). One of these patients also had unforeseen mediastinal nodal metastasis (pN2). Two patients underwent thoracotomy outside protocol after proven nodal invasion found by mediastinoscopy. In 1 of these patients, a bleeding complication occurred during mediastinoscopy, requiring the surgeon to convert to thoracotomy. For 1 patient in the endosonography group, the preoperative staging with endosonography and mediastinoscopy did not show locally advanced disease, but a second video bronchoscopy revealed invasion in the main carina (endoscopic T4), implying irresectability.

**Table 1.** Major Clinical Characteristics of Patients in Study

	Surgical Staging (n = 118)	Endosonography and Surgical Staging (n = 123)	P Value
Age, mean (SD), y	65 (9)	65 (9)	.94
Sex, No. (%)			
Male	87 (74)	99 (80)	.22
Female	31 (26)	24 (20)	
Indication for staging, No. (%)			
Known NSCLC	89 (75)	99 (80)	.36
Squamous cell carcinoma	44 (37)	46 (37)	
Adenocarcinoma	21 (18)	28 (23)	
Adenosquamous	2 (2)	3 (2)	
Large cell carcinoma	3 (3)	6 (5)	
Bronchoalveolar cell carcinoma	1 (1)	0	
Carcinoma not further specified	18 (15)	16 (13)	
Suspected NSCLC	29 (25)	24 (20)	
Tumor localization, No. (%)			
Left lower lobe	17 (14)	27 (22)	.29
Left upper lobe	18 (15)	25 (20)	
Right upper lobe	30 (25)	28 (23)	
Middle lobe	9 (8)	10 (8)	
Right lower lobe	44 (37)	33 (27)	
Tumor stage PET/CT, No. (%)			
T1	26 (22)	22 (18)	.47
T2	66 (56)	80 (65)	
T3	11 (9)	11 (9)	
T4	15 (13)	10 (8)	
Nodal status PET/CT, No. (%)			
N0	15 (13)	9 (7)	.39
N1	17 (14)	20 (16)	
N2	66 (56)	78 (63)	
N3	20 (17)	16 (13)	
Short axis of largest LN, mean (SD), mm	12 (5)	13 (4)	.16
ACCP classification, No. (%) <sup>a</sup>			
Massive enlargement (A)	0	0	.70
Discrete enlargement (B)	73 (62)	76 (62)	
Central tumor or hilar node (C)	35 (30)	33 (27)	
Nodes <10 mm (D)	10 (8)	14 (11)	
Final histopathology data, No. (%) <sup>b</sup>			
NSCLC	110 (93)	119 (97)	.25
Squamous cell carcinoma	47 (40)	51 (41)	
Adenocarcinoma	40 (34)	40 (33)	
Adenosquamous	5 (4)	6 (5)	
Large cell carcinoma	6 (5)	2 (2)	
Bronchoalveolar cell carcinoma	0	1 (1)	
Carcinoma not further specified	12 (10)	19 (15)	
Small cell carcinoma	1 (1)	4 (3)	
Benign lesion	5 (4)	0	
Unknown	2 (2)	0	

Abbreviations: ACCP, American College of Chest Physicians; LN, lymph node; NSCLC, non-small cell lung cancer; PET/CT, positron emission tomography/computed tomography.

<sup>a</sup>ACCP classification of lung cancer: subgroup A indicates patients with bulky mediastinal nodal disease or obvious mediastinal invasion (irresectable); B, enlarged LNs (short axis ≥10 mm); C, enlarged hilar LNs or centrally located primary lung lesion; and D, peripheral lung lesion without enlarged hilar or mediastinal LNs on CT. Patients with ACCP class D were included because of increased fluorodeoxyglucose uptake in at least 1 mediastinal LN station.

<sup>b</sup>Based on hierarchic availability of pathology reports obtained at thoracotomy, surgical staging, endosonography, or data available at randomization. For 2 patients with a suspicious lung lesion, no final histopathological diagnosis was obtained. Both had negative surgical staging; the first was treated with radiation therapy because he declined further surgical interventions, and the second declined all further interventions or therapy.

surgical staging vs 6 of 123 (5%; 95% CI, 2%-10%) in the endosonography group ( $P=.78$ ). Overall, 1 complication was directly related to endosonography (pneumothorax after biopsy of a lung lesion) while the 12 other were directly related to the surgical staging procedure. The most common adverse event was persistent hoarseness due to recurrent nerve palsy.

The sensitivity and NPVs for surgical staging vs endosonography alone without additional surgical staging was 79% (41/52; 95% CI, 66%-88%) vs 85% (56/66; 95% CI, 74%-92%) ( $P=.47$ ) and 86% (66/77; 95% CI, 76%-92%) vs 85% (57/67; 95% CI, 75%-92%), respectively ( $P>.99$ ). Complications occurred in 7 of 118 patients (6%; 95% CI, 3%-12%) after surgical staging and in 1 of 123 patients (1%; 95% CI, 0%-4%) following endosonography ( $P=.03$ ). Mediastinal nodal metastases after a negative endosonography were identified by surgical staging procedures in 6 of 65 patients (9%; 95% CI, 4%-19%), and complications occurred in 5 of these patients (8%; 95% CI, 3%-17%).

**COMMENT**

We have shown that commencing mediastinal nodal staging with endosonography significantly improves the detection of nodal metastases and reduces the rate of unnecessary thoracotomies by more than half compared with surgical staging alone, in patients with resectable NSCLC. This benefit is not associated with a greater rate of complications.

Imaging with CT and fluorodeoxyglucose PET is neither sensitive nor specific enough to detect the presence or absence of nodal metastasis, and therefore mediastinal tissue staging is frequently indicated in patients with nonmetastatic resectable lung cancer.<sup>4,5</sup> There is interest in combined modality mediastinal staging for patients with resectable lung cancer because missing mediastinal nodal metastases during preoperative surgical staging results in patients needlessly undergoing thoracotomy. Because almost all mediastinal

nodes can be covered, a combined endosonography investigation could be superior to surgical staging in the detection of nodal disease. Furthermore, endosonography does not require general anesthesia, is preferred by patients,<sup>13</sup> and is considered cost-effective<sup>21</sup> compared with surgical staging.

It has been demonstrated previously that the addition of EUS-FNA to mediastinoscopy can increase the sensitivity of detection of mediastinal nodal disease to 93%.<sup>13</sup> In that study, unnecessary thoracotomies could have been prevented in 1 of 6 patients using combined modality mediastinal staging.<sup>13</sup> In the present study, an unnecessary thoracotomy due to undetected mediastinal nodal metastases was prevented in 1 of 7 patients evaluated with the new staging strategy in comparison with immediate surgical staging. Because EBUS-TBNA accesses the same mediastinal nodes as mediastinoscopy,<sup>22</sup> it seems logical to combine EUS-FNA and EBUS-TBNA to replace mediastinoscopy to achieve a complete minimally invasive tissue staging of the mediastinum.<sup>23,24</sup> This concept was assessed in an observational study in patients suspected of having lung cancer and showed a sensitivity of 93% and an NPV of 97%.<sup>10</sup> Although these findings were promising, it should be acknowledged that selection bias may have influenced the results and that no answer about the value of endosonography compared with the current standard (surgical staging) was given.<sup>25</sup>

The current study used a randomized design,<sup>26</sup> was adequately powered, and was performed in a large and well-defined study population, which are all important assets for internal and external validity. Pathological assessment was performed according to gold standards for histology. Although the interpretation of fine-needle aspirates might raise some concern, we found that interobserver agreement between local pathologists and an external reference pathologist was excellent. Tissue samples obtained by endosonography are also suitable for molecular analysis.<sup>27</sup>

Given that the sensitivity of endosonography is similar to that of mediastinoscopy (85% vs 79%, respectively), and that endosonography is associated with a lower complication rate (1% vs 6% for mediastinoscopy), endosonography should be the first step for mediastinal nodal staging. Although we found that mediastinoscopy following a negative endosonography procedure did increase the sensitivity for detection of nodal metastases from 85% to 94%, it does mean that 11 patients need to undergo mediastinoscopy to identify 1 single patient with mediastinal nodal metastasis. Therefore, it is doubtful whether

all negative endosonography investigations should routinely be followed by mediastinoscopy or this strategy should be reserved for a certain subgroup.

A limitation of our study was that all investigations, including the surgical staging procedures, were performed in tertiary referral centers, potentially limiting the applicability of the study results. However, EUS-FNA and EBUS-TBNA are now incorporated as alternatives to surgical staging in international lung cancer staging guidelines.<sup>4,5</sup> Use of the EBUS-TBNA technique is increasing, and it has been shown that EUS-FNA can be implemented success-

**Table 2.** Diagnostic Performance<sup>a</sup>

Nodal Invasion, N2/N3	No./Total No. (%) [95% Confidence Interval]		P Value
	Surgical Staging (n = 118)	Endosonography and Surgical Staging (n = 123)	
Sensitivity	41/52 (79) [66-88]	62/66 (94) [85-98]	.02
Negative predictive value	66/77 (86) [76-92]	57/61 (93) [84-97]	.18

<sup>a</sup>Patient numbers and results are based on a multiple imputation procedure assigning values to missing data for mediastinal nodal status (n=8 for the surgical staging group and n=3 for the endosonography group), resulting in 1 additional patient with a nodal metastasis in the surgical staging group.

**Table 3.** Secondary Outcomes

	Surgical Staging, No. (n = 118)	Endosonography and Surgical Staging, No. (n = 123)	P Value
Unnecessary thoracotomies, all	21	9	.02
pN2	9	4	
Combination pN2/death	1	1	
Combination pN2/pT4	2	0	
Combination pN2/pM1	1	0	
pT4 <sup>a</sup>	6	1	
pM1	0	2	
Small cell lung cancer	0	1	
Exploratory thoracotomy	2	0	
Benign lesion	2	0	
Death within 30 days	2	1	.78
Complications, all	7	6	
Persistent hoarseness <sup>b</sup>	2	4	
Pneumothorax <sup>c</sup>	1	1	
Mediastinitis <sup>d</sup>	0	1	
Major bleeding	3	0	
Conversion to thoracotomy	1	0	

<sup>a</sup>None of these pT4 tumors were completely resected.  
<sup>b</sup>Hoarseness was considered a severe complication if it lasted >6 months and was attributable to the surgical staging procedures (mediastinoscopy).  
<sup>c</sup>The pneumothorax during endosonography occurred after a transesophageal ultrasound-guided fine-needle aspiration procedure during which the primary tumor was biopsied. With thoracic drainage, full lung expansion was achieved.  
<sup>d</sup>This patient presented with fever 24 hours after mediastinoscopy; treatment with antibiotics resulted in full recovery.

fully.<sup>28</sup> Another limitation is the lack of a generally accepted definition of unnecessary thoracotomy. However, the definition and the rate of unnecessary thoracotomies in the immediate surgical staging group of the present study (18%) are similar to those in a recent report.<sup>6</sup>

In conclusion, among patients with (suspected) NSCLC, a staging strategy combining endosonography and surgical staging compared with surgical staging alone resulted in greater sensitivity for mediastinal nodal metastases and fewer unnecessary thoracotomies.

**Author Contributions:** Dr Tournoy had full access to all of the data in the study and takes responsibility for the integrity of the data and the accuracy of the data analysis.

**Study concept and design:** Annema, van Meerbeeck, Rintoul, Braun, Versteegh, Rabe, Tournoy.

**Acquisition of data:** Annema, van Meerbeeck, Rintoul, Dooms, De Leyn, Braun, Carroll, de Ryck, Vermassen, Versteegh, Veselić, Nicholson, Rabe, Tournoy.

**Analysis and interpretation of data:** Annema, van Meerbeeck, Rintoul, Dooms, Deschepper, Dekkers, Praet, Vansteenkiste, Versteegh, Rabe, Tournoy.

**Drafting of the manuscript:** Annema, van Meerbeeck, Deschepper, Dekkers, Versteegh, Nicholson, Rabe, Tournoy.

**Critical revision of the manuscript for important intellectual content:** Annema, van Meerbeeck, Rintoul, Dooms, Deschepper, Dekkers, De Leyn, Braun, Carroll, Praet, de Ryck, Vansteenkiste, Vermassen, Versteegh, Veselić, Nicholson, Rabe, Tournoy.

**Statistical analysis:** Annema, Deschepper, Dekkers, Tournoy.

**Obtained funding:** van Meerbeeck, Rintoul, Tournoy. **Administrative, technical, or material support:** Annema, Rintoul, Dooms, Braun, Carroll, Praet, Vansteenkiste, Versteegh, Veselić, Rabe, Tournoy.

**Study supervision:** Annema, van Meerbeeck, Praet, Versteegh, Rabe, Tournoy.

**Financial Disclosures:** Drs Annema and Rabe reported that the Department of Pulmonology at Leiden University Medical Center received support for endosonography training courses from Hitachi Medical Systems (the Netherlands/Germany) and COOK (Ireland). Dr Rintoul reported that Papworth Hospital, Cambridge, received loan EBUS equipment and support for educational endosonography courses from Olympus UK. No other disclosures were reported.

**Funding/Support:** Local support for data collection at Ghent University Hospital was provided by the Zorg-

programma Oncologie Gent (ZOG) (Carla Vandena-beele, Ghent University Hospital). Data collection in Papworth Hospital was supported by the UK National Health Service R&D Health Technology Assessment Program (project No. 06/302/216). Drs Rintoul and Rassl were supported in part by the National Institute for Health Research Cambridge Biomedical Research Centre.

**Role of the Sponsor:** The funding sources had no role in the design and conduct of the study; in the collection, analysis, and interpretation of the data; or in the preparation, review, or approval of the manuscript.

**Previous Presentation:** Part of the data from this study was presented by Dr Tournoy at the Annual Meeting of the American Society of Clinical Oncology; Chicago, Illinois; June 5, 2010 (abstract 7000); and by Dr Annema at the Annual Congress of the European Respiratory Society; Barcelona, Spain; September 22, 2010 (abstract 5378).

**Additional Contributions:** We thank the ASTER data management team (Frauke Vandewalle; Tasja Verstraete; and George Van Maele, PhD, Ghent University Hospital); Martin Hiele, MD, PhD (Leuven University Hospitals); Doriss Rassl, FRCPath, and Francis Wells, FRCS (Papworth Hospital); all the staff at the participating centers; the referring chest physicians who have generously devoted their time to this study; and the patients for their participation. We thank Jan P. Vandenbroucke, MD, PhD (Leiden University Medical Center), for his advice. None received compensation for the contributions.

REFERENCES

1. Parkin DM, Bray F, Ferlay J, Pisani P. Global cancer statistics, 2002. *CA Cancer J Clin.* 2005;55(2):74-108.
2. Scott WJ, Howington J, Feigenberg S, Movsas B, Pisters K; American College of Chest Physicians. Treatment of non-small cell lung cancer stage I and stage II: ACCP evidence-based clinical practice guidelines (2nd edition). *Chest.* 2007;132(3)(suppl):2345-2425.
3. Robinson LA, Ruckdeschel JC, Wagner H Jr, Stevens CW; American College of Chest Physicians. Treatment of non-small cell lung cancer-stage IIIA: ACCP evidence-based clinical practice guidelines (2nd edition). *Chest.* 2007;132(3)(suppl):2435-2655.
4. De Leyn P, Lardinois D, Van Schil PE, et al. ESTS guidelines for preoperative lymph node staging for non-small cell lung cancer. *Eur J Cardiothorac Surg.* 2007;32(1):1-8.
5. Dettler FC, Jantz MA, Wallace M, Vansteenkiste J, Silvestri GA; American College of Chest Physicians. Invasive mediastinal staging of lung cancer: ACCP evidence-based clinical practice guidelines (2nd edition). *Chest.* 2007;132(3)(suppl):2025-2205.
6. Fischer B, Lassen U, Mortensen J, et al. Preoperative staging of lung cancer with combined PET-CT. *N Engl J Med.* 2009;361(1):32-39.
7. Handy JR Jr, Asaph JW, Skokan L, et al. What happens to patients undergoing lung cancer surgery? outcomes and quality of life before and after surgery. *Chest.* 2002;122(1):21-30.
8. Micames CG, McCrory DC, Pavey DA, Jowell PS, Gress FG. Endoscopic ultrasound-guided fine-needle aspiration for non-small cell lung cancer staging: a systematic review and meta-analysis. *Chest.* 2007;131(2):539-548.
9. Gu P, Zhao YZ, Jiang LY, Zhang W, Xin Y, Han BH. Endobronchial ultrasound-guided transbronchial needle aspiration for staging of lung cancer: a systematic review and meta-analysis. *Eur J Cancer.* 2009;45(8):1389-1396.
10. Wallace MB, Pascual JM, Raimondo M, et al. Mini-

11. Annema JT, Versteegh MI, Veselić M, Voigt P, Rabe KF. Endoscopic ultrasound-guided fine-needle aspiration in the diagnosis and staging of lung cancer and its impact on surgical staging. *J Clin Oncol.* 2005;23(33):8357-8361.
12. Tournoy KG, De Ryck F, Vanwalleghem LR, et al. Endoscopic ultrasound reduces surgical mediastinal staging in lung cancer: a randomized trial. *Am J Respir Crit Care Med.* 2008;177(5):531-535.
13. Annema JT, Versteegh MI, Veselić M, et al. Endoscopic ultrasound added to mediastinoscopy for preoperative staging of patients with lung cancer. *JAMA.* 2005;294(8):931-936.
14. Rintoul RC, Tournoy KG, El Daly H, et al. EBUS-TBNA for the clarification of PET positive intrathoracic lymph nodes: an international multi-centre experience. *J Thorac Oncol.* 2009;4(1):44-48.
15. Bhutani MS, Hawes RH, Hoffman BJ. A comparison of the accuracy of echo features during endoscopic ultrasound (EUS) and EUS-guided fine-needle aspiration for diagnosis of malignant lymph node invasion. *Gastrointest Endosc.* 1997;45(6):474-479.
16. Tournoy KG, Annema JT, Krasnik M, Herth FJ, van Meerbeeck JP. Endoscopic and endobronchial ultrasonography according to the proposed lymph node map definition in the seventh edition of the tumor, node, metastasis classification for lung cancer. *J Thorac Oncol.* 2009;4(12):1576-1584.
17. Mountain CF, Dresler CM. Regional lymph node classification for lung cancer staging. *Chest.* 1997;111(6):1718-1723.
18. Lardinois D, De Leyn P, Van Schil P, et al. ESTS guidelines for intraoperative lymph node staging in non-small cell lung cancer. *Eur J Cardiothorac Surg.* 2006;30(5):787-792.
19. Rami-Porta R, Wittekind C, Goldstraw P; International Association for the Study of Lung Cancer (IASLC) Staging Committee. Complete resection in lung cancer surgery: proposed definition. *Lung Cancer.* 2005;49(1):25-33.

20. Herth FJ, Eberhardt R, Krasnik M, Ernst A. Endobronchial ultrasound-guided transbronchial needle aspiration of lymph nodes in the radiologically and positron emission tomography-normal mediastinum in patients with lung cancer. *Chest.* 2008;133(4):887-891.
21. Harewood GC, Pascual J, Raimondo M, et al. Economic analysis of combined endoscopic and endobronchial ultrasound in the evaluation of patients with suspected non-small cell lung cancer. *Lung Cancer.* 2010;67(3):366-371.
22. Ernst A, Anantham D, Eberhardt R, Krasnik M, Herth FJ. Diagnosis of mediastinal adenopathy: real-time endobronchial ultrasound guided needle aspiration versus mediastinoscopy. *J Thorac Oncol.* 2008;3(6):577-582.
23. Rintoul RC, Skwarski KM, Murchison JT, Wallace WA, Walker WS, Penman ID. Endobronchial and endoscopic ultrasound-guided real-time fine-needle aspiration for mediastinal staging. *Eur Respir J.* 2005;25(3):416-421.
24. Vilman P, Krasnik M, Larsen SS, Jacobsen GK, Clementsen P. Transesophageal endoscopic ultrasound-guided fine-needle aspiration (EUS-FNA) and endobronchial ultrasound-guided transbronchial needle aspiration (EBUS-TBNA) biopsy: a combined approach in the evaluation of mediastinal lesions. *Endoscopy.* 2005;37(9):833-839.
25. Annema JT, Tournoy KG, Rabe KF. Lung cancer staging with minimally invasive endoscopic techniques. *JAMA.* 2008;299(21):2510-2511.
26. Bossuyt PM, Lijmer JG, Mol BW. Randomised comparisons of medical tests: sometimes invalid, not always efficient. *Lancet.* 2000;356(9244):1844-1847.
27. Garcia-Olivé I, Monsó E, Andreo F, et al. Endobronchial ultrasound-guided transbronchial needle aspiration for identifying EGFR mutations. *Eur Respir J.* 2010;35(2):391-395.
28. Annema JT, Bohoslavsky R, Burgers S, et al. Implementation of endoscopic ultrasound for lung cancer staging. *Gastrointest Endosc.* 2010;71(1):64-70.