Review

Glioblastoma and Other Malignant Gliomas
A Clinical Review

Antonio Omuro, MD; Lisa M. DeAngelis, MD

IMPORTANCE Glioblastomas and malignant gliomas are the most common primary malignant brain tumors, with an annual incidence of 5.26 per 100 000 population or 17 000 new diagnoses per year. These tumors are typically associated with a dismal prognosis and poor quality of life.

OBJECTIVE To review the clinical management of malignant gliomas, including genetic and environmental risk factors such as cell phones, diagnostic pitfalls, symptom management, specific antitumor therapy, and common complications.

EVIDENCE REVIEW Search of PubMed references from January 2000 to May 2013 using the terms *glioblastoma*, *glioma*, *malignant glioma*, *anaplastic astrocytoma*, *anaplastic oligodendroglioma*, *anaplastic oligoastrocytoma*, and *brain neoplasm*. Articles were also identified through searches of the authors' own files. Evidence was graded using the American Heart Association classification system.

FINDINGS Only radiation exposure and certain genetic syndromes are well-defined risk factors for malignant glioma. The treatment of newly diagnosed glioblastoma is based on radiotherapy combined with temozolomide. This approach doubles the 2-year survival rate to 27%, but overall prognosis remains poor. Bevacizumab is an emerging treatment alternative that deserves further study. Grade III tumors have been less well studied, and clinical trials to establish standards of care are ongoing. Patients with malignant gliomas experience frequent clinical complications, including thromboembolic events, seizures, fluctuations in neurologic symptoms, and adverse effects from corticosteroids and chemotherapies that require proper management and prophylaxis.

CONCLUSIONS AND RELEVANCE Glioblastoma remains a difficult cancer to treat, although therapeutic options have been improving. Optimal management requires a multidisciplinary approach and knowledge of potential complications from both the disease and its treatment.

JAMA. 2013;310(17):1842-1850. doi:10.1001/jama.2013.280319

CME Quiz at jamanetworkcme.com and **CME Questions** 1853

Author Affiliations: Department of Neurology, Memorial Sloan-Kettering Cancer Center, New York, New York.

Corresponding Author: Antonio Omuro, MD, Department of Neurology, Memorial Sloan-Kettering Cancer Center, 1275 York Ave, New York, NY 10065 (omuroa@mskcc.org).

Section Editor: Mary McGrae McDermott, MD, Senior Editor.

Malignant brain tumors are among the most feared types of cancer, not only for their poor prognosis, but also because of the direct repercussions on quality of life and cognitive function. Prevalence studies estimate that 138 054 patients had a diagnosis of a primary malignant brain tumor in the United States in 2010.[1] Malignant gliomas are the most common type of primary malignant brain tumor, accounting for 80% of patients and an annual incidence of 5.26 per 100 000 population, or 17 000 new cases diagnosed per year.[2] This disease is most common in the sixth through eighth decades of life[2]; the number of patients is expected to increase with the aging of the population.

Internists, family practitioners, and emergency physicians are likely to be the first to encounter patients with a primary brain tumor and will typically remain involved in their care throughout the entire disease course (**Box 1**). This review focuses on the practical aspects involved in the clinical management of malignant gliomas that such professionals may encounter.

Methods

References were identified through PubMed searches from 2000 to 2013, using the terms *glioblastoma*, *glioma*, *malignant glioma*, *anaplastic astrocytoma*, *anaplastic oligodendroglioma*, *anaplastic oligoastrocytoma*, and *brain neoplasm*. Articles were also identified through searches of the authors' own files. The American Heart Association classification of recommendations and levels of evidence was used to grade the quality of evidence.[3]

Downloaded From: http://jama.jamanetwork.com/ on 09/16/2014

Box 1. Symptoms at Presentation of Glioblastoma

Headache
Nausea/vomiting
Cognition changes
Personality changes
Gait imbalance
Urinary incontinence
Hemiparesis
Aphasia
Hemineglect
Visual field defect
Seizures

Table 1. Classification of Malignant Gliomas and Survival According to the Surveillance, Epidemiology, and End Results (SEER) Program Registry[2]

	Survival, %	
	1-Year	5-Year
WHO grade IV tumors[a]		
Glioblastoma and variants[b]	35.7	4.7
WHO grade III tumors[a]		
Anaplastic astrocytoma	60.1	25.9
Anaplastic oligodendroglioma	81	49.4
Anaplastic oligoastrocytomas	NA	NA

Abbreviations: NA, not available (diagnosis not captured in this database); WHO, World Health Organization.

[a] The WHO classification groups gliomas into 4 grades based on increasing degree of anaplasia and aggressiveness. Malignant gliomas comprise WHO grades III and IV tumors.

[b] Gliosarcoma, giant cell glioblastoma, and small cell glioblastoma.

Pathology and Risk Factors

The World Health Organization (WHO) classification system groups gliomas into 4 histological grades defined by increasing degrees of undifferentiation, anaplasia, and aggressiveness.[4] This review focuses on malignant gliomas (**Table 1**), by far the most common form of gliomas, which includes WHO grade IV tumors (glioblastoma and its variants) and grade III tumors (anaplastic variants of astrocytoma, oligodendroglioma, and oligoastrocytoma). WHO grade II tumors (diffuse astrocytomas, oligodendrogliomas, and oligoastrocytomas) are more differentiated neoplasms that invariably progress to a higher-grade tumor with time.

Glioblastoma accounts for 82% of cases of malignant glioma[2] and is characterized histologically by considerable cellularity and mitotic activity, vascular proliferation, and necrosis. Because cells in these tumors vary in size and shape, ie, they are pleomorphic, glioblastomas were called *glioblastoma multiforme*, a term no longer in use. Glioblastoma and other malignant gliomas are highly invasive, infiltrating surrounding brain parenchyma, yet they are typically confined to the central nervous system (CNS) and do not metastasize.

Malignant gliomas arise in a multistep process involving sequential and cumulative genetic alterations resulting from intrinsic and environmental factors. Gliomas are more common in men than women and in white rather than black populations. A number of rare hereditary syndromes are associated with an increased risk of glioma, including Cowden, Turcot, Li-Fraumeni, neurofibromatosis type 1 and type 2, tuberous sclerosis, and familial schwannomatosis.[5,6] A family history of glioma is rarely observed but, when present, is associated with a 2-fold increase in the risk of developing glioma. Genome-wide association studies have identified a few susceptibility variants such as 20q13.33 (*RTEL*), 5p15.33 (*TERT*), 9p21.3 (*CDKN2BAS*), 7p11.2 (*EGFR*), 8q24.21 (*CCDC26*), and 11q23.3 (*PHLDB1*), but these genes are only weakly associated with glioma, possibly reflecting multiple molecular subsets.[7,8] Gliomas are inversely associated with the presence of atopic diseases such as asthma, eczema, and hay fever.[9] Preventive measures, such as lifestyle changes, are ineffective in averting gliomas. Early diagnosis and treatment unfortunately do not improve outcomes, precluding the utility of screening for this disease.

Ionizing radiation is an established environmental risk factor for glioma development. This association was demonstrated in studies of children receiving cranial irradiation for cancer therapy and *Tinea capitis* and in individuals exposed to atomic bombs and nuclear weapons testing.[10] Most studies of radiation used in diagnostic procedures found no increased risk of glioma[10] except for a retrospective study in children undergoing computed tomography (CT) scans suggesting a risk excess, although the overall incidence remained low, with 1 excess brain tumor per 10 000 patients within 10 years after exposure to 1 CT scan.[11] Glioma risk is not increased from exposure to cell phones and other types of electromagnetic fields, head injury, foods containing *N*-nitroso compounds, aspartame, occupational risk factors, pesticides, or season of birth.[10] Cell phone risks have captured the public's attention, but associations between cell phone usage and glioma are not consistent.[12,13] Biological effects of radiofrequency on the brain include ipsilateral increases in cerebral blood flow[14] and glucose metabolism[15] during cell phone exposure, but most case-control studies have failed to demonstrate a relationship with the development of brain tumors. These studies are limited by several factors, including recall bias, variations in length of exposure and latency, and varying cell phone technologies used over time. Glioma incidence trends have not followed the explosion in cell phone use, mitigating against a glioma risk attributable to cell phones, but because trends could lag, continued surveillance is warranted, especially focusing on children who are exposed from an early age.[13]

From a molecular standpoint, malignant gliomas are highly heterogeneous tumors.[16] Genome-wide expression studies in glioblastomas revealed 4 transcriptional subclasses, displaying features reminiscent of distinct cell types: classical, mesenchymal, proneural, and neural.[17,18] The classical glioblastoma subclass typically displays chromosome 7 amplifications, chromosome 10 deletions, *EGFR* amplification, *EGFR* mutations (point and vIII mutations), and *Ink4a/ARF* locus deletion. The mesenchymal subclass displays a high frequency of *NF1* mutation/deletion and high expression of *CHI3L1*, *MET*, and genes involved in the tumor necrosis factor and nuclear factor–κB pathways. Proneural glioblastomas are characterized by alterations of *PDGFRA* and mutations in *IDH1* and *TP53*, sharing gene expression features with

Downloaded From: http://jama.jamanetwork.com/ on 09/16/2014

Box 2. Headache Characteristics That May Indicate the Presence of a Brain Tumor vs a Benign Headache

- Acute or recent onset over days or months (primary headaches are usually chronic and develop over several years); onset after age 50 years; change in the pattern of a chronic headache.
- Increasing intensity or frequency. Intensity may be variable, and tumor headache may respond to analgesics but progress to intractable headache.
- May awaken patient from sleep, even when mild (primary headaches usually awaken the patient when severe).
- Unilateral pain. The pain is restricted to the same side as the tumor (in migraine patients, the pain usually alternate sides from one episode to another).
- Accompanying focal symptoms (should be differentiated from migraine auras, which are fully reversible, usually develop over several minutes, and last less than 1 hour).
- Accompanying cognitive or behavioral symptoms (may be mistaken for dementia or psychiatric illnesses).
- Nausea and vomiting with headache (usually indistinguishable from migraines).
- Papilledema indicating intracranial hypertension but rarely seen at diagnosis because imaging is usually obtained at earlier disease stages.

lower-grade gliomas and secondary glioblastomas (ie, lower-grade gliomas that later recurred as glioblastoma). The neural subclass is characterized by the expression of neuronal markers. Many molecular abnormalities and mutations overlap across the transcriptional subclasses, for example, *PTEN* loss, and a large number of very rare mutations have been described in gliomas, adding to the interpatient heterogeneity.[19,20]

Clinical Presentation and Initial Evaluation

Headaches are relatively frequent, present in about 50% of patients at diagnosis, but usually with a nonspecific pain pattern[21]; progressive severity, unilateral localization, and new-onset headache in a patient older than 50 years are some of the features that may distinguish a tumor-associated headache from a benign headache (**Box 2**). Papilledema is associated with significantly intracranial pressure and is now rarely seen because imaging is usually obtained at earlier disease stages. Cognitive difficulties and personality changes may develop and are often mistaken for psychiatric disorders or dementia, particularly in elderly individuals. Gait imbalance and incontinence may be present, usually in larger tumors with significant mass effect. Focal signs such as hemiparesis, sensory loss, or visual field disturbances are common and reflect tumor location. Occasionally, the development of symptoms is rapid, mimicking a stroke. Language difficulties may be mistaken for confusion or delirium. Seizures are the presenting manifestation in about 20% to 40% of patients, and usually a focal onset is reported.[22]

Brain magnetic resonance imaging (MRI) with and without contrast is the diagnostic modality of choice when a brain tumor is suspected (class I, level B)[23]; CT scan is reserved for patients unable to undergo MRI (eg, those with pacemakers). Malignant gliomas typically enhance with gadolinium (**Figure**) and may have central areas of necrosis; they are characteristically surrounded by white matter edema. Tumors are often unifocal but can be multifocal. Findings on MRI can be indistinguishable from brain metastases.

A number of nonneoplastic syndromes may mimic malignant gliomas on neuroimaging,[24] including brain abscess, subacute stroke, multiple sclerosis, and other inflammatory diseases; looking for elements in the patient's history that point to those alternative diagnoses prior to surgery is imperative (**Table 2**). Additional testing such as cerebral angiogram, electroencephalography, or lumbar puncture is rarely indicated.

Symptomatic Treatment

Symptomatic relief ultimately relies on the efficacy of specific antitumor therapies, but corticosteroids may temporarily alleviate neurologic symptoms caused by peritumoral edema (Figure, C). Dexamethasone is often used because of its low mineralocorticoid activity. Initial doses are typically 12 to 16 mg/d in divided doses; given the high bioavailability, oral use is comparable with intravenous. Unfortunately, corticosteroid adverse effects can be substantial, and early tapering is indicated whenever possible. The presence of primary CNS lymphoma (PCNSL) should be considered before initiating corticosteroids because these agents are lympholytic and may obscure identification of lymphoma cells on histologic examination. On MRI, PCNSL usually displays a more uniform pattern of contrast enhancement, often described as "cotton" or "snowball," which tends to disappear rapidly with corticosteroids.[25] If PCNSL is suspected, corticosteroids should not be used until after a brain biopsy has been performed, in order to avoid diagnostic delays.

In patients who present with seizures, initiation of antiepileptics is required, but there is no evidence to support prophylactic use of antiepileptics in patients without seizures (class III, level B).[22] Levetiracetam is often preferred because it has a favorable toxicity profile, both oral and intravenous formulations are available, and it has no drug-to-drug interaction with most chemotherapeutic agents (class I, level B).[26] Other nonenzyme liver inducers may be used, such as topiramate, lamotrigine, valproic acid, and lacosamide. If possible, potent liver enzyme inducers such as phenytoin, carbamazepine, and phenobarbital should be avoided because they may decrease the effectiveness of some chemotherapeutic agents[27] and preclude participation in most clinical trials.

Neurosurgical Management

After neuroimaging, patients with suspected malignant glioma should be considered for surgical resection, aiming at relieving mass effect, achieving cytoreduction, and providing adequate tissue for histologic and molecular tumor characterization. In suspected low-grade gliomas, early surgical resection may also be indicated, providing more reliable tumor grading.[28] In inoperable tumors, stereotactic biopsy may be performed for histologic diagnosis, but the limited amount of tissue acquired may preclude full molecular characterization. Whenever possible, patients should be referred for sur-

Downloaded From: http://jama.jamanetwork.com/ on 09/16/2014

gery in tertiary care facilities, which provide optimized surgical tools (advanced intraoperative monitoring, awake mapping, and functional and intraoperative MRI)[29] and allow for adequate handling, processing, and storage of the tissue, including comprehensive molecular characterization and tissue profiling that may guide subsequent treatments.

Figure. Typical Glioblastoma Features on Magnetic Resonance Imaging Studies Used in the Initial Evaluation of a Suspected Brain Tumor

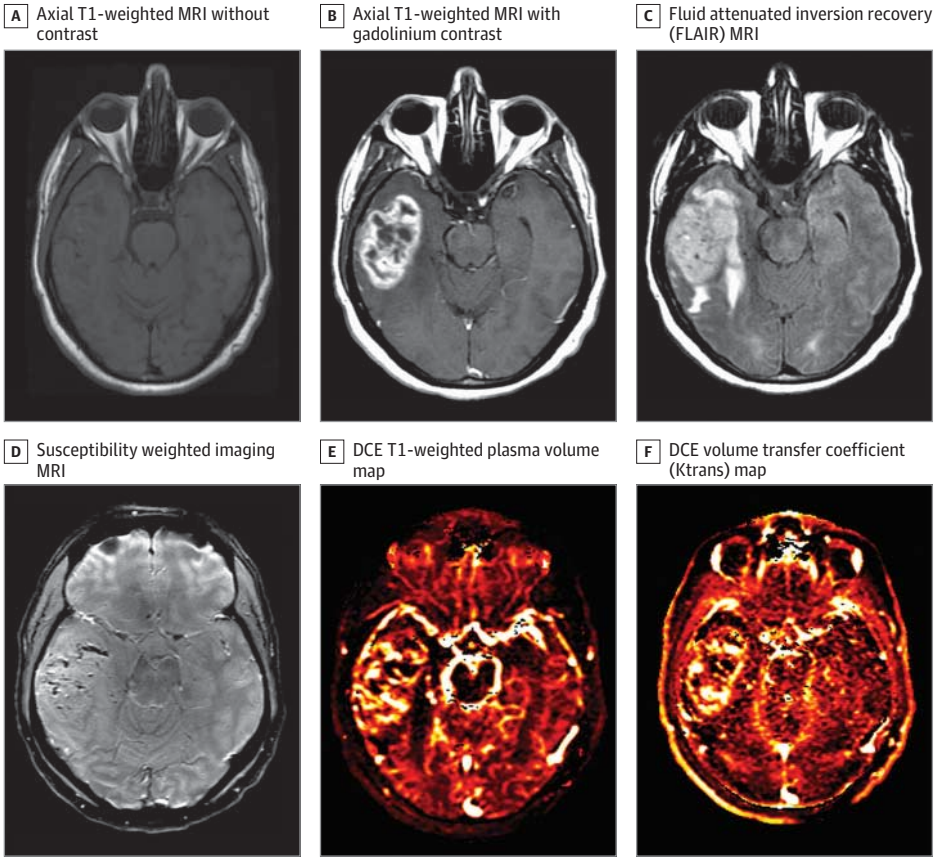

Brain magnetic imaging studies of a patient with a glioblastoma in the right temporal lobe. A, Axial T1-weighted magnetic resonance image (MRI) without contrast showing a poorly delineated right temporal mass lesion. Gadolinium contrast injection (B) reveals a heterogeneously enhancing cystic/necrotic lesion. C, Fluid attenuated inversion recovery sequence shows areas of hypersignal extending beyond the areas of contrast enhancement, corresponding to peritumoral edema, which typically improves with corticosteroids. D, Susceptibility weighted image shows hypointense areas corresponding to small intratumoral hemorrhagic components. E and F, Advanced imaging with dynamic contrast enhanced (DCE) T1 perfusion MRI further characterizes the neoplastic angiogenic process, showing areas of hyperperfusion on the plasma volume map (E) and increased vascular permeability (volume transfer coefficient [Ktrans] map) (F). (Images courtesy of Robert Young, MD, Memorial Sloan-Kettering Cancer Center.)

Table 2. History and Physical Examination Elements to Aid in the Differential Diagnosis Between Malignant Gliomas and Tumefactive Nonneoplastic Disorders

Clinical Elements	Differential Diagnosis to Consider	Action Prior to Biopsy or Surgical Resection
Abrupt symptoms onset	Stroke	Look for vascular territory distribution and gyral patterns of enhancement; DWI may have negative results
Onset in young adults	AIDS and other infectious or inflammatory lesions	HIV testing
Recent dental procedure, ears/nose/throat infection	Brain abscess	Hyperintensity on DWI
History of immunosuppression	Fungal and other opportunistic infections, primary CNS lymphoma	Homogeneous enhancement suggests lymphoma; consider LP and avoid corticosteroids until biopsy
History of autoimmune or inflammatory disease (patient or family)	Multiple sclerosis, sarcoidosis, Behçet syndrome	Look for small white matter lesions on MRI
IV drug addiction	Brain abscess, syphilis, AIDS	Obtain blood cultures
Exposure to tuberculosis, even if remote	Tuberculoma	Chest imaging, PPD test
Travel to countries with endemic infectious diseases	Cysticercosis, hydatidosis, and amebiasis	Look for calcifications on CT and scolex on MRI (cysticercosis); consider LP
History of subtle/transient neurologic deficits or visual symptoms	Multiple sclerosis and demyelinating diseases	Other lesions usually present on MRI
History or presence of oral or genital ulcers	Behçet syndrome	
Rashes	Sarcoidosis, AIDS, Behçet syndrome	

Abbreviations: CNS, central nervous system; CT, computed tomography; DWI, diffusion-weighted magnetic resonance imaging; HIV, human immunodeficiency virus; IV, intravenous; LP, lumbar puncture; MRI, magnetic resonance imaging; PPD, purified protein derivative.

Downloaded From: http://jama.jamanetwork.com/ on 09/16/2014

Specific Treatments

Glioblastoma

First-Line Adjuvant Treatment

After surgery, adjuvant radiotherapy combined with chemotherapy should be considered in all patients. The typical radiotherapy dose is 60 Gy divided in 30 fractions. The use of intensity-modulated radiotherapy has been increasingly preferred because of better targeting capability, but to date there is no evidence of superiority over other focal radiotherapy techniques. Because this is a diffusely infiltrative disease, there is currently no defined role for stereotactic radiosurgery or brachytherapy as part of first-line treatment.[30]

The DNA alkylating agent temozolomide is administered orally, concomitantly with radiotherapy, followed by an adjuvant course (class I, level B). The use of this regimen is supported by a randomized phase 3 study[31] that found the addition of temozolomide increased the median survival to 15 months vs 12 months with radiotherapy alone (hazard ratio, 0.63; $P < .001$). The 2-year survival rate was 27% vs 10%, respectively. A post hoc tissue analysis suggested patients with tumors displaying promoter methylation of the DNA repair enzyme O6-methylguanine-DNA methyltransferase (MGMT) were more likely to benefit from the addition of temozolomide to radiotherapy.[32] Optimal treatments for elderly patients and patients with poor performance status remain to be established, although radiotherapy alone and temozolomide alone have both been shown effective and well tolerated, even in the older population.[33-36]

In addition to temozolomide, the other agent approved by the US Food and Drug Administration (FDA) for first-line treatment is biodegradable polymers containing the alkylating agent carmustine, implanted into the tumor bed after tumor resection. A phase 3 trial has suggested a modest survival benefit,[37] but that study had several methodological problems, which in the setting of frequent toxicities, such as brain edema, infection, and seizures, precluded wide adoption of this treatment (class III, level B). Moreover, a direct comparison with standard chemoradiotherapy with temozolomide is lacking.

After chemoradiotherapy, many patients, especially those with methylated MGMT promoter tumors,[38] present with increased tumor size and mass effect that correspond to radiotherapy effects, rather than treatment failure.[39] This process, termed *pseudoprogression*, poses a challenging diagnostic problem, given that some patients may be experiencing real tumor progression and require a change in treatment. Magnetic resonance imaging perfusion may be helpful when it shows decreased relative cerebral blood volume (rCBV), suggesting pseudoprogression,[40] but in patients with increased rCBV, the diagnostic dilemma remains. Common practice is to continue with adjuvant temozolomide with close radiographic follow-up if patients are asymptomatic and consider corticosteroids, surgery, or alternative treatments such as bevacizumab if patients are highly symptomatic.

Bevacizumab, a humanized vascular endothelial growth factor (VEGF) monoclonal antibody that targets angiogenesis, is under study in first-line glioblastoma treatment, added to chemoradiotherapy with temozolomide. Preliminary results of 2 large randomized trials demonstrated increased progression-free survival (PFS) but not overall survival with the addition of bevacizumab.[41,42] Until the significance of these findings is clear, bevacizumab is usually reserved for salvage treatment, discussed later in this section.

Treatment for Recurrence

After first-line treatment, virtually all glioblastoma patients experience disease progression after a median PFS of 7 to 10 months.[43] Unfortunately, none of the available salvage treatments has clearly shown improved survival and likely only benefit selected patients. Treatment choices should be individualized, and clinical trials strongly considered.

Surgical resection may be considered for mass effect relief, cytoreduction, and updating histology and molecular characteristics of the tumor, although survival benefits are unclear. Many clinical trials only enroll patients who are surgical candidates, allowing for preoperative drug exposure and then evaluation of tumor tissue to ascertain whether the new agent had the intended effect on the molecular target; such trials should be considered in all surgical candidates. However, for a majority of patients, surgery will not be indicated because of tumor location, widespread disease in the brain, or the patient's poor physical performance status.

Salvage chemotherapy options include bevacizumab, temozolomide rechallenge, and other alkylating agents, such as nitrosoureas (carmustine and lomustine) and carboplatin (**Table 3**). Bevacizumab is a frequently used treatment for recurrent glioblastoma. This agent targets VEGF, a key proangiogenic factor involved in tumor progression. Vascular endothelial growth factor also promotes vascular permeability, and therefore bevacizumab often results in rapid decrease of peritumoral edema and facilitates corticosteroid taper. In a phase 2 study[44] testing single-agent bevacizumab and bevacizumab combined with irinotecan, the response rates (RRs) were 28% to 39% and 6-month PFS was 42% to 50%, which compared favorably with historical controls (RR, 5%-9%; 6-month PFS, 15%-20%). However, survival benefits are less clear, with median survival of 8 months, as compared with 6 to 7 months for historical controls; randomized studies in recurrent disease are ongoing. Bevacizumab is an option for highly symptomatic patients who might benefit from decreased brain edema and tumor shrinkage, either with initial treatment or at recurrence (class IIa, level B).[41,42,44]

Metronomic temozolomide dosing schedules (ie, given at lower doses for extended periods of time)[45-47] are another salvage therapy option with a favorable toxicity profile, which may be particularly helpful in early tumor progression after radiotherapy or for patients who have completed the adjuvant temozolomide and experience recurrence while not receiving treatment. Carmustine and lomustine have traditionally been the mainstay of recurrent glioblastoma treatment,[48] but hematotoxicity rates are high and efficacy is modest. Recently, the use of low-intensity alternating electric fields applied to the brain through a portable device (NovoTTF-100A; Novocure) has received FDA approval for recurrent glioblastoma. Approval was based on a phase 3 trial[49] showing equivalent efficacy and a superior toxicity profile in the device group relative to a control group consisting of the treating physician's choice of chemotherapy. However, the device's efficacy was modest, and a noninferiority design, required for this type of comparison, was not used; the role of NovoTTF-100A in glioblastoma remains unclear (class IIb, level B). After temozolomide and bevacizumab fail, the

Downloaded From: http://jama.jamanetwork.com/ on 09/16/2014

Table 3. Frequently Used Malignant Glioma Chemotherapy Regimens, Common Dosing Schedules, and Frequent Complications

Drug	Common Doses	Frequent or Worrisome Complications (Nonexhaustive List)
Temozolomide	Concomitant with radiotherapy: 75 mg/m^2 daily Adjuvant: 150-200 mg/m^2 (5/28 days) Salvage (metronomic) schedules: 50 mg/m^2 daily 75 mg/m^2 daily (21/28 days) 150 mg/m^2 daily (7/14 days)	Lymphopenia, consider pneumocystis prophylaxis (other cytopenias relatively rare)
		Nausea and vomiting (requires premedication with 5-HT3 antagonists)
		Hepatitis B reactivation (screening prior to initiation of therapy recommended; prophylaxis recommended if serologic evidence of previous contact, eg, entecavir, 0.5 mg daily)
		Elevated liver enzymes (usually benign and reversible)
		Rash (usually manageable with antihistaminics and corticosteroid premedication)
Bevacizumab	10 mg/kg every 2 wk	Hypertension (usually manageable with standard antihypertensives)
		Proteinuria (requires monthly monitoring with urinalysis or urine/plasma creatinine ratio; usually benign but may evolve to nephrotic syndrome, thrombotic microangiopathy, and renal failure)
		Venous thromboembolic events (manageable with anticoagulation; low-molecular-weight heparin compounds preferred)
		Arterial thromboembolic events (usually require permanent discontinuation of the drug)
		Wound healing delays (monitoring of craniotomy wound healing advised; elective surgeries call for discontinuation of the drug for a month)
		Infusion reaction (benign, usually manageable) Tumor bleeding (rare, usually consisting of an asymptomatic finding on MRI)
		Hematotoxicity rare but often used in combination with other agents; aggressive management of thrombocytopenia advisable
BCNU (carmustine)	200 mg/m^2 every 6-8 wk	Hematotoxicity and thrombocytopenia frequent and sometimes severe; nadir is very delayed (5-6 wk)
		Pulmonary fibrosis (requires baseline pulmonary function test prior to initiation of treatment and monitoring of cumulative dose)
PCV (procarbazine, CCNU, and vincristine)		Overall a fairly toxic regimen
Procarbazine	110 mg/m^2 day 1/56	Toxicity profile similar to BCNU
CCNU (lomustine)	60 mg/m^2 days 8-21/56	Toxicity profile similar to temozolomide; potential for serotonin syndrome (requires low tyramine diet, avoid precipitating medications, alcohol)
Vincristine	1.4 mg/m^2 days 8 and 29/56	Peripheral neuropathy frequent, requires dose capping at 2 mg
Carboplatin	AUC 5-6 mg/mL/min	Hematologic toxicity frequent
		Requires monitoring of renal function for dose adjustments
		Highly emetic (requires preantiemetic and postantiemetic regimen)
Irinotecan	125 mg/m^2 every 2 wk (for patients not taking enzyme-inducing antiepileptics)	Diarrhea may be severe; requires early and aggressive treatment from onset
	340 mg/m^2 every 2 wk (for patients taking enzyme inducers)	Hematologic toxicity

Abbreviations: AUC, area under the curve; MRI, magnetic resonance imaging.

prognosis is extremely reserved, and the median survival is 3 to 4 months, with no therapeutic options available.

Anaplastic (WHO Grade III) Astrocytoma

Because anaplastic astrocytoma is a relatively rare disease, the treatment is often based on principles established in glioblastomas. After surgery, the first line of treatment is radiotherapy. The role of chemotherapy has not been established in randomized trials. A phase 3 trial investigating the addition of temozolomide is ongoing. However, off trial, many physicians recommend a treatment similar to glioblastoma using radiotherapy and concomitant temozolomide, followed by adjuvant temozolomide (class IIa, level C).[50] After radiotherapy, recurrence is expected, and patients usually progress to develop a secondary glioblastoma. Salvage treatments used for glioblastoma are also used for anaplastic astrocytoma, particularly cytotoxic agents. Bevacizumab may be less effective in grade III tumors than in glioblastoma and, until further studies are done, should be reserved for end-stage disease (class III, level C).[51,52] With aggressive treatment, the median overall survival of grade III astrocytomas remains in the range of 2 to 3 years.

Anaplastic (WHO Grade III) Oligodendrogliomas

Tumors with oligodendroglial components have distinctive histologic features such as perinuclear clearing, giving rise to a "fried egg" appearance, and a reticular pattern of blood vessel growth and are characterized by the presence of co-deletion of 1p/19q chromosomes, resulting from an unbalanced translocation of 19p to 1q. These tumors are more responsive to therapy than their grade III astrocytoma counterparts, with a median survival of 3 to 6 years compared with 2 to 3 years for grade III astrocytoma. Addition of chemotherapy to radiotherapy prolongs progression-free and overall survival (class IIa, level A), as demonstrated in two phase 3 trials.[53,54] Those studies, conducted in the 1990s, used a fairly toxic combination of procarbazine, CCNU (lomustine), and vincristine (PCV). While those trials were in progress, temozolomide became widely available,[55] and ongoing clinical trials are investigating whether this agent can replace PCV.

Mixed Grade III Gliomas

These tumors are characterized by the histological coexistence of both astrocytic and oligodendroglial features. Because oligodendroglial features are typically associated with a better prognosis,

Downloaded From: http://jama.jamanetwork.com/ on 09/16/2014

Box 3. Key Aspects in the Clinical Management and Follow-up of Patients With Malignant Gliomas

- Antiepileptics are indicated in patients with seizures, but primary prophylaxis is not required in patients who never experienced a seizure. Levetiracetam is the preferred antiepileptic, given its excellent toxicity profile and lack of interactions with most chemotherapy agents; adjustments in doses are needed in case of renal failure.
- Magnetic resonance imaging of the brain is the examination of choice for baseline and follow-up evaluations.
- Radiographic worsening shortly after radiotherapy may reflect treatment effects (pseudoprogression), rather than tumor progression.
- Minor fluctuations in symptoms are common in brain tumors, but sudden or marked neurologic changes (sudden onset of severe headaches, repeated seizures or status epilepticus, new focal deficits) should prompt urgent evaluation
- Sudden clinical worsening may be caused by tumor progression, but other causes include tumor bleeding, nonconvulsive status epilepticus, infection, corticosteroids adverse effects or withdrawal, and electrolyte and other metabolic disorders.
- A computed tomographic scan of the head without contrast is advisable to rule out tumor bleeding in patients with sudden clinical worsening. Aggressive management of chemotherapy-related thrombocytopenia is warranted to prevent tumor bleeding.
- Electroencephalography may be helpful in the evaluation of patients with unexplained symptoms worsening or confusion, to rule out nonconvulsive status epilepticus and subclinical seizures.
- Corticosteroids may be used for symptoms improvement but tapered off as soon as possible to minimize adverse effects; corticosteroid-associated hyperglycemia must be aggressively managed.
- Patients receiving chemotherapy and corticosteroids should be periodically evaluated for symptoms of oral candidiasis, mucositis, pneumocystosis, hepatitis B reactivation, skin rashes, and liver dysfunction, in addition to specific chemotherapy adverse effects (Table 3).
- Deep venous thrombosis and pulmonary embolism are frequent and require active monitoring and investigation of potential symptoms.
- Whenever required, therapeutic anticoagulation may be used; low-molecular-weight heparin compounds are preferred over warfarin.
- Patients of childbearing potential require contraception and fertility preservation discussion and counseling.
- Prior to aggressive workup for clinical complications or invasive procedures, assessment of disease stage and discussion with treating physician is warranted; if active treatment options have been exhausted, comfort care may be preferable instead.

these patients have been grouped with the anaplastic oligodendrogliomas. However, the histological classification of mixed gliomas is associated with high interexaminer variability, and therefore molecular classification based on 1p/19q co-deletion is often used. Tumors with 1p/19q deletions are usually treated as anaplastic oligodendrogliomas, and those without are treated as anaplastic astrocytomas (class IIa, level C).[55]

Management of Clinical Complications of Malignant Gliomas

The key aspects in the management of malignant gliomas are summarized in **Box 3**. Fluctuation of neurologic symptoms is the norm throughout the disease course. Not all symptoms warrant evaluation in an emergency department setting. Minor headaches that abate with analgesics and partial seizures in a patient with known seizures may be managed in an outpatient setting. However, rapid or significant neurologic deterioration, sudden onset of severe headache, and repeated seizures or status epilepticus require emergency attention. At the emergency department, evaluation should include a noncontrast CT scan of the head to exclude acute intratumoral bleeding and to characterize life-threatening tumor progression with mass effect; other treatable causes of neurologic deterioration should also be excluded.

Thromboembolic events are a frequent complication resulting from the cancer-related prothrombotic state, as well as certain treatments such as chemotherapy and bevacizumab, aggravated by neurologic deficits and immobilization.[56] Venous thromboembolic disease is particularly frequent, occurring in 20% to 30% of patients. Therefore, anticoagulants should be used prophylactically during hospitalization in all patients and also considered in nonambulatory patients in the outpatient setting. A low threshold for investigation with a CT scan of the chest or lower extremity ultrasound Doppler is advisable in patients with chest pain, dyspnea, increased respiratory rate or other respiratory symptoms, or lower extremity edema. The presence of the brain tumor or treatment with bevacizumab does not constitute a formal contraindication for anticoagulation. Low-molecular-weight heparin compounds are preferred because they can be reversed easily in case of CNS hemorrhage. If anticoagulation is contraindicated, such as in recent craniotomy or intracranial hemorrhage, inferior vena cava filters may be used, but unfortunately complications are frequent, including occlusion and embolism recurrence.[57]

Corticosteroid-related hyperglycemia is common, resulting in increased morbidity and compromised tumor control.[58] Corticosteroids increase insulin resistance, and treatment is similar to type 2 diabetes.[59] Options include metformin, sulfonylureas, and thiazolidinediones, although an insulin regimen is sometimes necessary, individualized to address the fluctuations in glucose levels that reflect the pharmacokinetics and pharmacodynamic effects of the corticosteroid regimen used. Managing hyperglycemia is particularly challenging in the setting of the often frequent fluctuations in dexamethasone doses, requiring close collaboration between the internist and neuro-oncologist. Corticosteroid-related myopathy, manifested by proximal muscle weakness with trouble taking stairs and walking, is another frequent complication that should be distinguished from tumor progression. Other corticosteroid complications that require active monitoring and prompt intervention include confusion, personality changes, insomnia, and weight gain.

Frequent chemotherapy complications are summarized in Table 3. Most glioma regimens are relatively mild, and febrile neutropenia is rare. However, aggressive management of thrombocytopenia is warranted because of the risk of CNS bleeding, especially when bevacizumab is used. Pneumocystosis prophylaxis should be considered, given frequent lymphopenia with low CD4 counts and corticosteroid use.[60] Oral candidiasis is common and should be differentiated from chemotherapy-related mucositis, which is relatively rare. Hepatitis B screening should be considered in patients prior to initiating chemotherapy; patients previously exposed to hepatitis should receive prophylactic treatment, such as entecavir.[61,62] Chemotherapy-related skin rashes may develop but are usually manageable and rarely lead to treatment discontinuation.

Downloaded From: http://jama.jamanetwork.com/ on 09/16/2014

Given the overall poor prognosis for glioblastoma, early discussion of palliative care and comfort care measures is recommended. It is important to establish advanced directives early in the course of disease; unlike other types of cancer, brain tumor patients may lose mental capacity unexpectedly and in the midst of active treatment, leaving family and proxies in the challenging situation of making treatment choices and defining goals of care.

Conclusions and Future Directions

Although malignant glioma remains an incurable disease, treatment options have been expanding and improving because of better understanding of the complex molecular biology of these tumors, their microenvironment, and immunologic interactions with the host. Several novel promising therapies are under evaluation, including trials of targeted agents directed at receptor tyrosine kinases and signal transduction pathways, alternative antiangiogenic agents, gene therapy, immunotherapy, reirradiation, radiolabeled drugs, and many others. Such treatments address the marked tumor heterogeneity, and many are being designed for very specific and small subgroups of patients whose tumors share distinct molecular and genetic characteristics. Participation in clinical trials and molecular screening of large numbers of patients are important to improving the care of future patients.

ARTICLE INFORMATION

Author Contributions: Dr Omuro had full access to all of the data in the study and takes responsibility for the integrity of the data and the accuracy of the data analysis.
Study concept and design: Omuro, DeAngelis.
Acquisition of data: Omuro.
Analysis and interpretation of data: Omuro.
Drafting of the manuscript: Omuro, DeAngelis.
Critical revision of the manuscript for important intellectual content: Omuro, DeAngelis.
Administrative, technical, or material support: Omuro, DeAngelis.
Study supervision: Omuro, DeAngelis.

Conflict of Interest Disclosures: Both authors have completed and submitted the ICMJE Form for Disclosure of Potential Conflicts of Interest. Dr Omuro reported having served on advisory boards for Roche La Hoffman, Novocure, and Schering-Plough/Merck. Dr DeAngelis reported having served as a consultant to the NFL Players Association, received grants from the Clinical and Translational Science Center, received royalties from Oxford, and received travel reimbursements as a board member for the American Academy of Neurology.

Additional Contributions: We are grateful to Robert Young, MD, Memorial Sloan-Kettering Cancer Center, for providing images for the Figure. He did not receive compensation for his contribution.

Submissions: We encourage authors to submit papers for consideration as a Review. Please contact Mary McGrae McDermott, MD, at mdm608@northwestern.edu.

REFERENCES

1. Porter KR, McCarthy BJ, Freels S, Kim Y, Davis FG. Prevalence estimates for primary brain tumors in the United States by age, gender, behavior, and histology. *Neuro Oncol*. 2010;12(6):520-527.

2. Dolecek TA, Propp JM, Stroup NE, Kruchko C. CBTRUS statistical report: primary brain and central nervous system tumors diagnosed in the United States in 2005-2009. *Neuro Oncol*. 2012;14(suppl 5):v1-v49.

3. Gibbons RJ, Smith S, Antman E; American College of Cardiology; American Heart Association. American College of Cardiology/American Heart Association clinical practice guidelines: Part I: where do they come from? *Circulation*. 2003;107(23):2979-2986.

4. Louis DN, Ohgaki H, Wiestler OD, Cavenee WK. *WHO Classification of Tumours of the Central Nervous System*. 4th ed. Lyon, France: International Agency for Research on Cancer; 2007.

5. Hottinger AF, Khakoo Y. Update on the management of familial central nervous system tumor syndromes. *Curr Neurol Neurosci Rep*. 2007;7(3):200-207.

6. Gu J, Liu Y, Kyritsis AP, Bondy ML. Molecular epidemiology of primary brain tumors. *Neurotherapeutics*. 2009;6(3):427-435.

7. Shete S, Hosking FJ, Robertson LB, et al. Genome-wide association study identifies five susceptibility loci for glioma. *Nat Genet*. 2009;41(8):899-904.

8. Rajaraman P, Melin BS, Wang Z, et al. Genome-wide association study of glioma and meta-analysis. *Hum Genet*. 2012;131(12):1877-1888.

9. Linos E, Raine T, Alonso A, Michaud D. Atopy and risk of brain tumors: a meta-analysis. *J Natl Cancer Inst*. 2007;99(20):1544-1550.

10. Bondy ML, Scheurer ME, Malmer B, et al; Brain Tumor Epidemiology Consortium. Brain tumor epidemiology: consensus from the Brain Tumor Epidemiology Consortium. *Cancer*. 2008;113(7)(suppl):1953-1968.

11. Pearce MS, Salotti JA, Little MP, et al. Radiation exposure from CT scans in childhood and subsequent risk of leukaemia and brain tumours: a retrospective cohort study. *Lancet*. 2012;380(9840):499-505.

12. Hardell L, Carlberg M, Hansson Mild K. Use of mobile phones and cordless phones is associated with increased risk for glioma and acoustic neuroma. *Pathophysiology*. 2013;20(2):85-110.

13. Corle C, Makale M, Kesari S. Cell phones and glioma risk: a review of the evidence. *J Neurooncol*. 2012;106(1):1-13.

14. Huber R, Treyer V, Schuderer J, et al. Exposure to pulse-modulated radio frequency electromagnetic fields affects regional cerebral blood flow. *Eur J Neurosci*. 2005;21(4):1000-1006.

15. Volkow ND, Tomasi D, Wang GJ, et al. Effects of cell phone radiofrequency signal exposure on brain glucose metabolism. *JAMA*. 2011;305(8):808-813.

16. Theeler BJ, Yung WK, Fuller GN, De Groot JF. Moving toward molecular classification of diffuse gliomas in adults. *Neurology*. 2012;79(18):1917-1926.

17. Verhaak RG, Hoadley KA, Purdom E, et al; Cancer Genome Atlas Research Network. Integrated genomic analysis identifies clinically relevant subtypes of glioblastoma characterized by abnormalities in *PDGFRA*, *IDH1*, *EGFR*, and *NF1*. *Cancer Cell*. 2010;17(1):98-110.

18. Phillips HS, Kharbanda S, Chen R, et al. Molecular subclasses of high-grade glioma predict prognosis, delineate a pattern of disease progression, and resemble stages in neurogenesis. *Cancer Cell*. 2006;9(3):157-173.

19. Bredel M, Scholtens DM, Harsh GR, et al. A network model of a cooperative genetic landscape in brain tumors. *JAMA*. 2009;302(3):261-275.

20. Yadav AK, Renfrow JJ, Scholtens DM, et al. Monosomy of chromosome 10 associated with dysregulation of epidermal growth factor signaling in glioblastomas. *JAMA*. 2009;302(3):276-289.

21. Forsyth PA, Posner JB. Headaches in patients with brain tumors: a study of 111 patients. *Neurology*. 1993;43(9):1678-1683.

22. Glantz MJ, Cole BF, Forsyth PA, et al; Report of the Quality Standards Subcommittee of the American Academy of Neurology. Practice parameter: anticonvulsant prophylaxis in patients with newly diagnosed brain tumors. *Neurology*. 2000;54(10):1886-1893.

23. Bradley WG Jr, Waluch V, Yadley RA, Wycoff RR. Comparison of CT and MR in 400 patients with suspected disease of the brain and cervical spinal cord. *Radiology*. 1984;152(3):695-702.

24. Omuro AM, Leite CC, Mokhtari K, Delattre JY. Pitfalls in the diagnosis of brain tumours. *Lancet Neurol*. 2006;5(11):937-948.

25. Bühring U, Herrlinger U, Krings T, Thiex R, Weller M, Küker W. MRI features of primary central nervous system lymphomas at presentation. *Neurology*. 2001;57(3):393-396.

26. Maschio M, Dinapoli L, Sperati F, et al. Levetiracetam monotherapy in patients with brain tumor-related epilepsy: seizure control, safety, and quality of life. *J Neurooncol*. 2011;104(1):205-214.

27. Perucca E. Clinically relevant drug interactions with antiepileptic drugs. *Br J Clin Pharmacol*. 2006;61(3):246-255.

28. Jakola AS, Myrmel KS, Kloster R, et al. Comparison of a strategy favoring early surgical resection vs a strategy favoring watchful waiting in low-grade gliomas. *JAMA*. 2012;308(18):1881-1888.

29. Sherman JH, Hoes K, Marcus J, Komotar RJ, Brennan CW, Gutin PH. Neurosurgery for brain tumors: update on recent technical advances. *Curr Neurol Neurosci Rep*. 2011;11(3):313-319.

Downloaded From: http://jama.jamanetwork.com/ on 09/16/2014

30. Tsao MN, Mehta MP, Whelan TJ, et al. The American Society for Therapeutic Radiology and Oncology (ASTRO) evidence-based review of the role of radiosurgery for malignant glioma. *Int J Radiat Oncol Biol Phys*. 2005;63(1):47-55.

31. Stupp R, Mason WP, van den Bent MJ, et al; European Organisation for Research and Treatment of Cancer Brain Tumor and Radiotherapy Groups; National Cancer Institute of Canada Clinical Trials Group. Radiotherapy plus concomitant and adjuvant temozolomide for glioblastoma. *N Engl J Med*. 2005;352(10):987-996.

32. Hegi ME, Diserens AC, Gorlia T, et al. MGMT gene silencing and benefit from temozolomide in glioblastoma. *N Engl J Med*. 2005;352(10):997-1003.

33. Keime-Guibert F, Chinot O, Taillandier L, et al; Association of French-Speaking Neuro-Oncologists. Radiotherapy for glioblastoma in the elderly. *N Engl J Med*. 2007;356(15):1527-1535.

34. Malmström A, Grønberg BH, Marosi C, et al; Nordic Clinical Brain Tumour Study Group (NCBTSG). Temozolomide versus standard 6-week radiotherapy versus hypofractionated radiotherapy in patients older than 60 years with glioblastoma: the Nordic randomised, phase 3 trial. *Lancet Oncol*. 2012;13(9):916-926.

35. Wick W, Platten M, Meisner C, et al; NOA-08 Study Group of Neuro-oncology Working Group (NOA) of German Cancer Society. Temozolomide chemotherapy alone versus radiotherapy alone for malignant astrocytoma in the elderly: the NOA-08 randomised, phase 3 trial. *Lancet Oncol*. 2012;13(7):707-715.

36. Holdhoff M, Rosner GL, Alcorn S, Grossman SA. "Elderly" patients with newly diagnosed glioblastoma deserve optimal care. *J Neurooncol*. 2013;113(2):343-344.

37. Westphal M, Hilt DC, Bortey E, et al. A phase 3 trial of local chemotherapy with biodegradable carmustine (BCNU) wafers (Gliadel wafers) in patients with primary malignant glioma. *Neuro Oncol*. 2003;5(2):79-88.

38. Brandes AA, Franceschi E, Tosoni A, et al. MGMT promoter methylation status can predict the incidence and outcome of pseudoprogression after concomitant radiochemotherapy in newly diagnosed glioblastoma patients. *J Clin Oncol*. 2008;26(13):2192-2197.

39. de Wit MC, de Bruin HG, Eijkenboom W, Sillevis Smitt PA, van den Bent MJ. Immediate post-radiotherapy changes in malignant glioma can mimic tumor progression. *Neurology*. 2004;63(3):535-537.

40. Young RJ, Gupta A, Shah AD, et al. MRI perfusion in determining pseudoprogression in patients with glioblastoma. *Clin Imaging*. 2013;37(1):41-49.

41. Gilbert MR, Dignam J, Won M, et al. RTOG 0825: phase III double-blind placebo-controlled trial evaluating bevacizumab (Bev) in patients (Pts) with newly diagnosed glioblastoma (GBM). *J Clin Oncol*. 2013;31(suppl):1.

42. Wick W, Cloughesy TF, Nishikawa R, et al. Tumor response based on adapted Macdonald criteria and assessment of pseudoprogression (PsPD) in the phase III AVAglio trial of bevacizumab (Bv) plus temozolomide (T) plus radiotherapy (RT) in newly diagnosed glioblastoma (GBM). *J Clin Oncol*. 2013;31(suppl):2002.

43. Omuro AM, Faivre S, Raymond E. Lessons learned in the development of targeted therapy for malignant gliomas. *Mol Cancer Ther*. 2007;6(7):1909-1919.

44. Friedman HS, Prados MD, Wen PY, et al. Bevacizumab alone and in combination with irinotecan in recurrent glioblastoma. *J Clin Oncol*. 2009;27(28):4733-4740.

45. Omuro A, Chan TA, Abrey LE, et al. Phase II trial of continuous low-dose temozolomide for patients with recurrent malignant glioma. *Neuro Oncol*. 2013;15(2):242-250.

46. Perry JR, Bélanger K, Mason WP, et al. Phase II trial of continuous dose-intense temozolomide in recurrent malignant glioma: RESCUE study. *J Clin Oncol*. 2010;28(12):2051-2057.

47. Wick A, Felsberg J, Steinbach JP, et al. Efficacy and tolerability of temozolomide in an alternating weekly regimen in patients with recurrent glioma. *J Clin Oncol*. 2007;25(22):3357-3361.

48. Batchelor TT, Mulholland P, Neyns B, et al. Phase III randomized trial comparing the efficacy of cediranib as monotherapy, and in combination with lomustine, vs lomustine alone in patients with recurrent glioblastoma. *J Clin Oncol*. 2013;31(26):3212-3218.

49. Stupp R, Wong ET, Kanner AA, et al. NovoTTF-100A versus physician's choice chemotherapy in recurrent glioblastoma: a randomised phase III trial of a novel treatment modality. *Eur J Cancer*. 2012;48(14):2192-2202.

50. Yung WK, Prados MD, Yaya-Tur R, et al; Temodal Brain Tumor Group. Multicenter phase II trial of temozolomide in patients with anaplastic astrocytoma or anaplastic oligoastrocytoma at first relapse. *J Clin Oncol*. 1999;17(9):2762-2771.

51. Seystahl K, Wiestler B, Hundsberger T, et al. Bevacizumab alone or in combination with irinotecan in recurrent WHO grade II and grade III gliomas. *Eur Neurol*. 2013;69(2):95-101.

52. Delios AM, Brennan CW, Huse JT, Colevas K, Omuro AMP. Bevacizumab for recurrent WHO grade III anaplastic glioma (AG). *J Clin Oncol*. 2012;30(suppl):2028.

53. van den Bent MJ, Brandes AA, Taphoorn MJ, et al. Adjuvant procarbazine, lomustine, and vincristine chemotherapy in newly diagnosed anaplastic oligodendroglioma: long-term follow-up of EORTC brain tumor group study 26951. *J Clin Oncol*. 2013;31(3):344-350.

54. Cairncross G, Wang M, Shaw E, et al. Phase III trial of chemoradiotherapy for anaplastic oligodendroglioma: long-term results of RTOG 9402. *J Clin Oncol*. 2013;31(3):337-343.

55. Abrey LE, Louis DN, Paleologos N, et al; Oligodendroglioma Study Group. Survey of treatment recommendations for anaplastic oligodendroglioma. *Neuro Oncol*. 2007;9(3):314-318.

56. Perry JR. Thromboembolic disease in patients with high-grade glioma. *Neuro Oncol*. 2012;14(suppl 4):iv73-iv80.

57. Kalva SP, Chlapoutaki C, Wicky S, Greenfield AJ, Waltman AC, Athanasoulis CA. Suprarenal inferior vena cava filters: a 20-year single-center experience. *J Vasc Interv Radiol*. 2008;19(7):1041-1047.

58. Link TW, Woodworth GF, Chaichana KL, et al. Hyperglycemia is independently associated with post-operative function loss in patients with primary eloquent glioblastoma. *J Clin Neurosci*. 2012;19(7):996-1000.

59. Kwon S, Hermayer KL. Glucocorticoid-induced hyperglycemia. *Am J Med Sci*. 2013;345(4):274-277.

60. Mahindra AK, Grossman SA. Pneumocystis carinii pneumonia in HIV negative patients with primary brain tumors. *J Neurooncol*. 2003;63(3):263-270.

61. Weinbaum CM, Mast EE, Ward JW. Recommendations for identification and public health management of persons with chronic hepatitis B virus infection. *Hepatology*. 2009;49(5)(suppl):S35-S44.

62. Grewal J, Dellinger CA, Yung WK. Fatal reactivation of hepatitis B with temozolomide. *N Engl J Med*. 2007;356(15):1591-1592.

Downloaded From: http://jama.jamanetwork.com/ on 09/16/2014