

should be distinguished from rationing and that parsimony is a virtue to which all physicians should strive in the practice of medicine.<sup>2</sup>

However, we disagree with the statement in the article that “Both parsimonious medicine and rationing aim to reduce resource use.” The aim of medical parsimony is to provide the care necessary for the patient’s good, not to reduce resource use (although it may in addition preserve resources<sup>3</sup>)—a difference in intention that helps form the foundation for the ethical distinction between parsimonious medicine and rationing.

We suspect Tilburt and Cassel might agree because they note the role of beneficence and nonmaleficence in underpinning parsimony. But language is important, and in this case it should not confuse a well-developed rationale for parsimony in medical practice.

David A. Fleming, MD, MA  
Lois Snyder Sulmasy, JD

**Author Affiliations:** Department of Medicine, University of Missouri School of Medicine, Columbia (Dr Fleming); and American College of Physicians Center for Ethics and Professionalism, Philadelphia, Pennsylvania (Ms Snyder Sulmasy; lsnyder@acponline.org).

**Conflict of Interest Disclosures:** The authors have completed and submitted the ICMJE Form for Disclosure of Potential Conflicts of Interest. Dr Fleming reported being the unpaid chair of the American College of Physicians Ethics, Professionalism, and Human Rights Committee. Ms Snyder Sulmasy reported being a full-time employee of the American College of Physicians.

1. Tilburt JC, Cassel CK. Why the ethics of parsimonious medicine is not the ethics of rationing. *JAMA*. 2013;309(8):773-774.
2. Snyder L; American College of Physicians Ethics, Professionalism, and Human Rights Committee. American College of Physicians ethics manual: sixth edition. *Ann Intern Med*. 2012;156(1 pt 2):73-104.
3. Pellegrino ED, Thomasma DC. *For the Patient's Good: the Restoration of Beneficence in Health Care*. New York, NY: Oxford University Press; 1988.

**In Reply:** Words do matter. Our summary paragraph may have unnecessarily muddied the clear water we were promoting. The suspicion of Dr Fleming and Ms Snyder Sulmasy is correct; we agree with their distinction. Strictly speaking, parsimonious medicine cannot and ought not aim ultimately at reducing resources, even if that is one of its collateral effects. We argue that very point in our article.

However, in a broader sense, a contemporary practice of medicine that intends the good of the patient as its ultimate target in a context characterized by overconsumption may (more often than not) end up aiming at the patient’s good through the proximate scope of parsimonious medicine—a scope that in modern medicine must involve restraint in many cases to achieve its patient-centered end. In restraint, rationing and parsimonious medicine share some resemblances even though their ends differ in ethically crucial ways.

Jon Tilburt, MD  
Christine Cassel, MD

**Author Affiliations:** Division of General Internal Medicine, Mayo Clinic, Rochester, Minnesota (Dr Tilburt) (tilburt.jon@mayo.edu); and American Board of Internal Medicine, Philadelphia, Pennsylvania (Dr Cassel).

**Conflict of Interest Disclosures:** The authors have completed and submitted the ICMJE Form for Disclosure of Potential Conflicts of Interest and none were reported.

## RESEARCH LETTER

### Retinal Vessel Leakage at High Altitude

**To the Editor:** Exposure to high altitude can cause acute mountain sickness (AMS) and, in severe cases, cerebral or pulmonary edema. Capillary leakage has been hypothesized to play a role in the pathogenesis of AMS, although the mechanism of altitude-related illnesses remains largely unknown. As a directly observable part of the brain, the retina offers a window to study altitude-related vascular changes of the central nervous system.

High-altitude retinopathy is characterized by optic disc edema, retinal hemorrhages, cotton wool spots, and increased tortuosity and dilation of retinal vessels.<sup>1,2</sup> Vessel leakage in the retinal periphery has not been investigated. Our objective was to assess retinal vessel integrity at high altitude using fluorescein angiography.

**Methods.** Fourteen healthy, unacclimatized volunteers (7 male and 7 female white participants aged 25-54 years; mean [SD] age, 35 [4] years) were recruited from the University of Tübingen by mass e-mail and studied at baseline (341 m), after ascent to 4559 m within 24 hours, and more than 14 days after return by fluorescein angiography with a confocal scanning laser ophthalmoscope (Spectralis, Heidelberg Engineering). Photographs were independently graded in random order by 4 masked ophthalmologists for presence and location of leakage.

To quantify the severity of AMS, the Lake Louise (LL) and AMS cerebral (AMS-C) scores<sup>3</sup> containing self-reported and objective clinical evaluation were acquired. The cutoff criterion for AMS was LL score (range, 0-15) of 5 or greater and AMS-C score (range, 0-4.99) of 0.7 or greater. Peripheral oxygen saturation (SpO<sub>2</sub>) was measured by pulse oximeter.

Correlations were tested using the Fisher exact test and differences between SpO<sub>2</sub> levels were analyzed using an independent, 2-sided *t* test at a significance level of *P* < .05; JMP version 8.0.2 statistical software was used (SAS Institute Inc). The study was approved by the ethics committee of the University of Tübingen; all participants gave written informed consent.

**Results.** Retinal abnormalities were not noted at baseline in any of the participants. At high altitude, marked bilateral leakage of peripheral retinal vessels was observed in 7 of 14 participants (50%; FIGURE 1). Leakage uniformly occurred in the following distinct pattern: always present in the temporal-inferior and absent in the nasal-superior periphery (FIGURE 2), favoring venules more than arterioles. Staining of the optic disc was detected in 57% (8/14); no leakage was found in the central retina (Figure 2).

All findings completely reversed after descent (Figure 1). Incidence of AMS at high altitude was 50% (7/14). Leakage was not correlated with AMS (LL, *P* = .90; AMS-C, *P* = .86) as 4 of 7 participants without AMS (57%) and 3 of 7 with

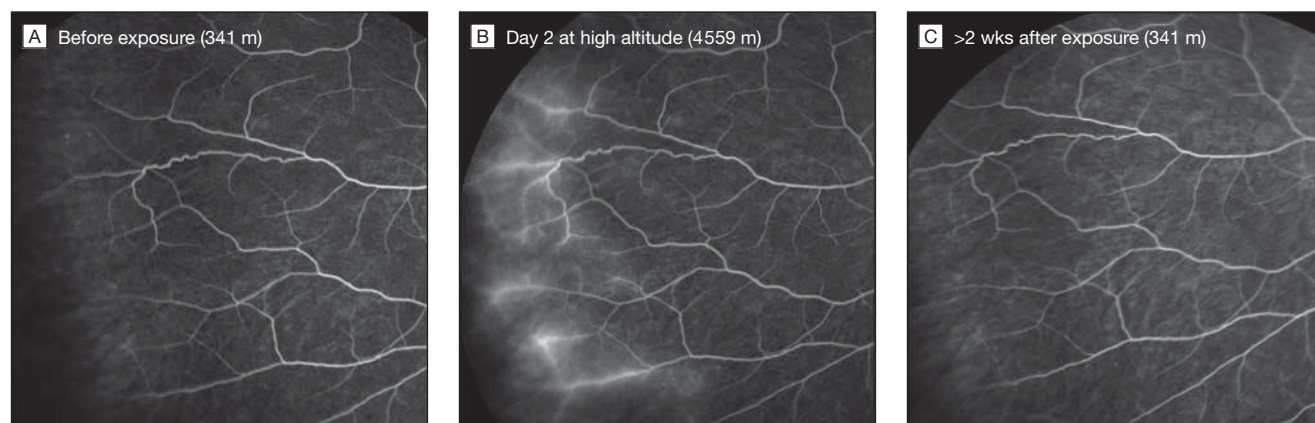
AMS (43%) showed leakage in an undistinguishable pattern. Leakage did not correlate with levels of SpO<sub>2</sub> (with leakage, 70.1% [95% CI, 64.8%-75.5%]; without leakage, 74.1% [95% CI, 68.9%-79.4%];  $P = .21$ ). No significant difference in SpO<sub>2</sub> was noted in participants with (71.1% [95% CI, 64.4%-77.9%]) or without AMS (73.1% [95% CI, 69.2%-77.1%]) ( $P = .54$ ). Only 1 participant showed a retinal hemorrhage; there was no leakage detectable in the area of hemorrhage.

**Discussion.** We found bilateral leakage of retinal vessels during altitude exposure with a uniform presentation in the

temporal peripheral crescent. To our knowledge, this finding in the most distal vascular bed of the retina (where tissue hypoxia is most severe) has not been detected in previous studies.<sup>4,5</sup> Retinal capillary leakage should be considered a part of the spectrum of high-altitude retinopathy.

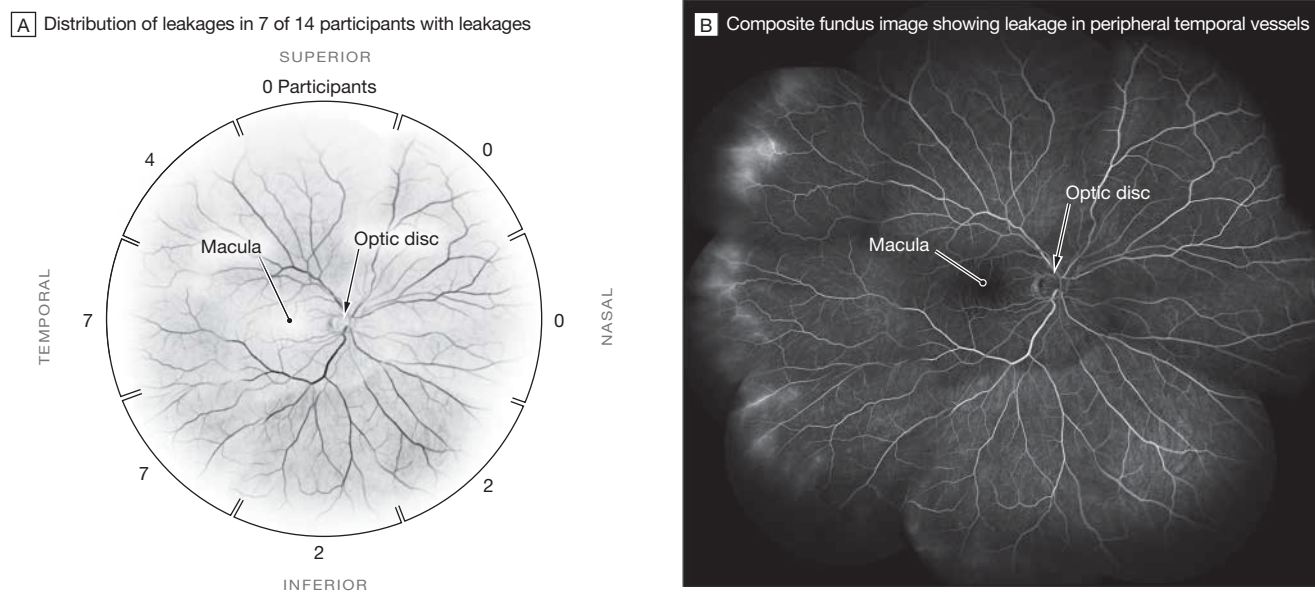
A comparable hemispherical presentation occurs in zone III of retinopathy of prematurity.<sup>6</sup> Leakage of retinal vessels with vasogenic edema of surrounding tissue suggests impairment in the tight junctions of the retinal capillary endothelial cells, the blood-retinal barrier. Whether similar disruptions in the blood-brain barrier cause AMS is unknown,

**Figure 1.** Fluorescein Angiography Showing Leakage of Peripheral Retinal Vessels in 1 Participant at High Altitude



At baseline altitude (left) peripheral retinal vasculature shows no fluorescein leakage while at high altitude (center) marked leakage is visible in the wide temporal periphery. Findings completely reversed after return to baseline altitude (right). This participant had no symptoms of acute mountain sickness (Lake Louise score: 0; acute mountain sickness cerebral score: 0.18).

**Figure 2.** Distribution of Leakage of Retinal Vessels in 7 Participants and Composite Fundus Image Showing Leakage in 1 Participant



Although none of the participants showed leakage in the nasal-superior periphery, all showed leakages in the temporal periphery.

but (taking into account the moderate sample size of this study) the lack of correlation between the retinal findings and AMS does not support this hypothesis.

Gabriel Willmann, MD  
M. Dominik Fischer, MD  
Andreas Schatz, MD  
Kai Schommer, MD  
Florian Gekeler, MD

**Author Affiliations:** Centre for Ophthalmology, University of Tübingen, Tübingen, Germany (Drs Willmann, Fischer, Schatz, and Gekeler) (gekeler@uni-tuebingen.de); and Department of Sports Medicine, Medical Clinic, University of Heidelberg, Heidelberg, Germany (Dr Schommer).

**Author Contributions:** Dr Gekeler had full access to all of the data in the study and takes responsibility for the integrity of the data and the accuracy of the data analysis.

*Study concept and design:* Willmann, Gekeler.

*Acquisition of data:* Willmann, Fischer, Schatz, Schommer, Gekeler.

*Analysis and interpretation of data:* Willmann, Fischer, Schatz, Schommer, Gekeler.

*Drafting of the manuscript:* Willmann, Schatz, Gekeler.

*Critical revision of the manuscript for important intellectual content:* Willmann, Fischer, Schatz, Schommer, Gekeler.

*Statistical analysis:* Schatz.

*Obtained funding:* Willmann, Fischer, Gekeler.

*Administrative, technical, or material support:* Willmann, Fischer, Gekeler.

*Study supervision:* Willmann, Schatz, Schommer, Gekeler.

**Conflict of Interest Disclosures:** The authors have completed and submitted the ICMJE Form for Disclosure of Potential Conflicts of Interest. Dr Gekeler reported serving as a consultant to Retina Implant AG. No other author reported disclosures.

**Funding/Support:** The study was supported by the Charles S. Houston Award from the Wilderness Medical Society. Heidelberg Engineering (Heidelberg, Germany) provided the confocal scanning laser ophthalmoscope.

**Role of the Sponsor:** The sponsor had no role in the design and conduct of the study; collection, management, analysis, and interpretation of the data; and preparation, review, or approval of the manuscript; and decision to submit the manuscript for publication.

**Additional Contributions:** We thank Peter Bärtsch, MD (Department of Sports Medicine, Medical Clinic, University of Heidelberg, Heidelberg, Germany), for invaluable

intellectual support during conception of our study, evaluation of data, and drafting of the manuscript. We also thank Faik Gelisken, MD (Centre for Ophthalmology, University of Tübingen, Tübingen, Germany), for critical review of our findings and grading of angiographies. Neither Dr Bärtsch nor Dr Gelisken received compensation for his contribution.

1. Singh I, Khanna PK, Srivastava MC, Lal M, Roy SB, Subramanyam CS. Acute mountain sickness. *N Engl J Med*. 1969;280(4):175-184.
2. McFadden DM, Houston CS, Sutton JR, Powles AC, Gray GW, Roberts RS. High-altitude retinopathy. *JAMA*. 1981;245(6):581-586.
3. Roach RC, Bartsch P, Oelz O, et al; Lake Louise Consensus Committee. The Lake Louise acute mountain sickness scoring system. In: *Hypoxia and Molecular Medicine*. Burlington, VT: Charles S. Houston; 1993:272-274.
4. Frayser R, Houston CS, Bryan AC, Rennie ID, Gray G. Retinal hemorrhage at high altitude. *N Engl J Med*. 1970;282(21):1183-1184.
5. Frayser R, Houston CS, Gray GW, Bryan AC, Rennie ID. The response of the retinal circulation to altitude. *Arch Intern Med*. 1971;127(4):708-711.
6. Albert DM, Miller JW, Azar DT, Blodi BA. *Albert & Jakobiec's Principles and Practice of Ophthalmology*. 3rd ed. Philadelphia, PA: Saunders/Elsevier; 2008.

## CORRECTIONS

**Incomplete References:** In the Viewpoint entitled "Why the Ethics of Parsimonious Medicine Is Not the Ethics of Rationing," published in the February 27, 2013, issue of *JAMA* (2013;309[8]:773-774), 2 references were omitted. In the second paragraph of the article, a reference citation should have appeared after "parsimonious medicine," citing: Snyder L. *American College of Physicians Ethics Manual*: sixth edition. *Ann Intern Med*. 2012;156(1 pt 2):73-104. In the second paragraph under the "The Ethics of Parsimonious Medicine" heading, a reference citation should have appeared after "care that does not benefit patients," citing: Pellegrino ED. Rationing health care: the ethics of medical gatekeeping. *J Contemp Health Law Policy*. 1986;2:23-45. This article has been corrected online.

**Incorrect Value in Abstract:** In the Review entitled "Benefits and Harms of CT Screening for Lung Cancer: a Systematic Review," published in the June 13, 2012, issue of *JAMA* (2012;307[22]:2418-2429), a value in the abstract was presented incorrectly. The lung cancer-specific mortality for the low-dose computed tomography group in the National Lung Screening Trial should have been 247 events per 100 000 person-years. This article has been corrected online.