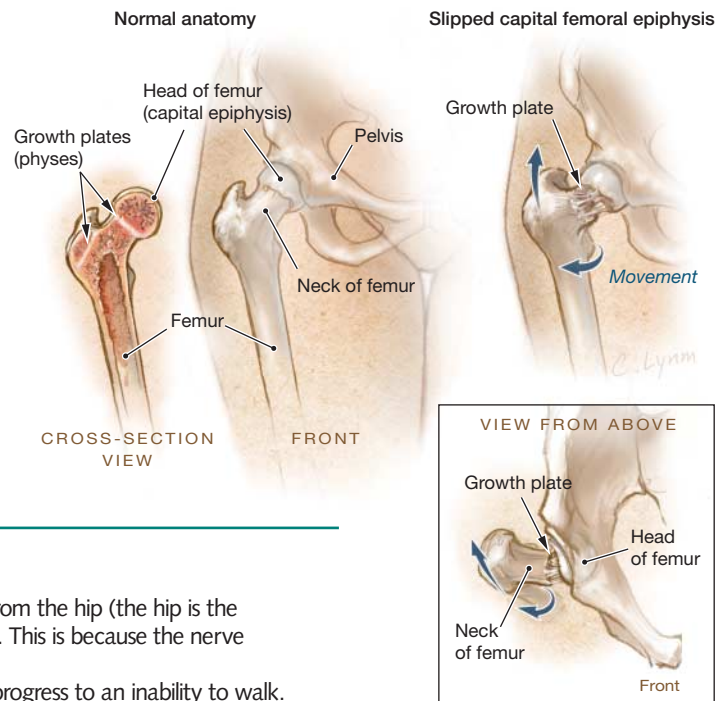


# Slipped Capital Femoral Epiphysis

**S**lipped capital femoral epiphysis (SCFE) is an orthopedic condition of children and adolescents. The epiphysis is the end of a long bone and is joined to the bone at the growth plate (physis). In SCFE, the physis in the head of the femur (thigh bone) becomes loose. As a result, the epiphysis separates from the rest of the bone and the femur moves out of alignment in the hip joint.

This condition affects approximately 10 in 100 000 adolescents in the United States. It is most commonly found in adolescents who are male, African American, and obese. Because it involves the growing portion of the bone, SCFE does not occur in children who have finished growing. It can affect just one hip or both hips. The severity is based on how much of the epiphysis has slipped off of the femur. The cause is unknown.



## SYMPTOMS

- History of limping
- Groin pain or knee pain. This is usually **referred** pain from the hip (the hip is the actual source, even though the pain is felt elsewhere). This is because the nerve that senses hip pain also senses pain in the knee.
- Varying degrees of pain over a long period. This can progress to an inability to walk.
- The hip on the affected side may be **flexed** (bent), with the knee pointing outward (**external rotation of the hip**).
- Difficulty fully straightening the leg on the affected side

## DIAGNOSIS

- X-rays of the hips in the early stages of SCFE show a widened physis with **osteopenia** (reduced bone mass) of the **neck** (narrow portion) of the femur.
- In later stages of SCFE, the epiphyses can have separated from the rest of the femur, appearing much like an ice cream cone with the ice cream portion sliding off the cone.

## TREATMENT AND FOLLOW-UP

- The goal of treatment is to prevent the femoral epiphysis from slipping further.
- SCFE requires surgical treatment. An **orthopedic surgeon**, a physician who specializes in correcting bone deformities or injuries, may place surgical screws or pins to hold the bones in place and prevent further slipping.
- Children with SCFE must be followed up closely to see if it develops in the other hip.
- Children with a history of severe SCFE may develop arthritis. They may also develop **avascular necrosis** of the top of the femur, a condition in which the bone's blood supply is interrupted, leading to death of the bone tissue.

Sources: Massachusetts General Hospital, American Academy of Orthopaedic Surgeons

## FOR MORE INFORMATION

- Massachusetts General Hospital  
[www.massgeneral.org/ortho/services/pediatrics/slipped\\_capital\\_femoral\\_epiphysis.aspx](http://www.massgeneral.org/ortho/services/pediatrics/slipped_capital_femoral_epiphysis.aspx)
- American Academy of Orthopaedic Surgeons  
[orthoinfo.aaos.org/topic.cfm?topic=a00052](http://orthoinfo.aaos.org/topic.cfm?topic=a00052)

## INFORM YOURSELF

To find this and previous JAMA Patient Pages, go to the Patient Page index on JAMA's website at [www.jama.com](http://www.jama.com). Many are available in English and Spanish.

Ann R. Punnoose, MD, Writer

Cassio Lynn, MA, Illustrator

Robert M. Golub, MD, Editor

The JAMA Patient Page is a public service of JAMA. The information and recommendations appearing on this page are appropriate in most instances, but they are not a substitute for medical diagnosis. For specific information concerning your personal medical condition, JAMA suggests that you consult your physician. This page may be photocopied noncommercially by physicians and other health care professionals to share with patients. To purchase bulk reprints, call 312/464-0776.

