Clinical Characteristics and Cardiovascular Magnetic Resonance Findings in Stress (Takotsubo) Cardiomyopathy

Ingo Eitel, MD
Florian von Knobelsdorff-Brenkenhoff, MD
Peter Bernhardt, MD
Iacopo Carbone, MD
Kai Muellerleile, MD
Annachiara Aldrovandi, MD
Marco Francone, PhD
Steffen Desch, MD
Matthias Gutberlet, MD
Oliver Strohm, MD
Gerhard Schuler, MD
Jeanette Schulz-Menger, MD
Holger Thiele, MD
Matthias G. Friedrich, MD

Context Stress cardiomyopathy (SC) is a transient form of acute heart failure triggered by stressful events and associated with a distinctive left ventricular (LV) contraction pattern. Various aspects of its clinical profile have been described in small single-center populations, but larger, multicenter data sets have been lacking so far. Furthermore, it remains difficult to quickly establish diagnosis on admission.

Objectives To comprehensively define the clinical spectrum and evolution of SC in a large population, including tissue characterization data from cardiovascular magnetic resonance (CMR) imaging; and to establish a set of CMR criteria suitable for diagnostic decision making in patients acutely presenting with suspected SC.

Design, Setting, and Patients Prospective study conducted at 7 tertiary care centers in Europe and North America between January 2005 and October 2010 among 256 patients with SC assessed at the time of presentation as well as 1 to 6 months after the acute event.

Main Outcome Measures Complete recovery of LV dysfunction.

Results Eighty-one percent of patients (n=207) were postmenopausal women, 8% (n=20) were younger women (aged ≤50 years), and 11% (n=29) were men. A stressful trigger could be identified in 182 patients (71%). Cardiovascular magnetic resonance imaging data (available for 239 patients [93%]) revealed 4 distinct patterns of regional ventricular ballooning: apical (n=197 [82%]), biventricular (n=81 [34%]), midventricular (n=40 [17%]), and basal (n=2 [1%]). Left ventricular ejection fraction was reduced (48% [SD, 11%]; 95% confidence interval [CI], 47%-50%) in all patients. Stress cardiomyopathy was accurately identified by CMR using specific criteria: a typical pattern of LV dysfunction, myocardial edema, absence of significant necrosis/fibrosis, and markers for myocardial inflammation. Follow-up CMR imaging showed complete normalization of LV ejection fraction (66% [SD, 7%]; 95% CI, 64%-68%) and inflammatory markers in the absence of significant fibrosis in all patients.

Conclusions The clinical profile of SC is considerably broader than reported previously. Cardiovascular magnetic resonance imaging at the time of initial clinical presentation may provide relevant functional and tissue information that might aid in the establishment of the diagnosis of SC.

JAMA. 2011;306(3):277-286 www.jama.com

Stress cardiomyopathy (SC), first reported in Japan as *takotsubo*, is characterized by acute, profound, but reversible left ventricular (LV) dysfunction in the absence of significant coronary artery disease, triggered by acute emotional or physical stress.[1] This phenomenon is identified by a distinctive pattern of "apical ballooning" and primarily affects postmenopausal women.[2-5] The majority of patients have a clinical presentation similar to that of acute coronary syndrome (ACS). Accordingly, international guidelines have included SC as an important differential diagnosis of ACS.[6]

The precise incidence of SC is unknown, but recent studies revealed a prevalence of approximately 2% of patients presenting with ACS in the United States and Europe.[2,4,5] Considerable evidence suggests that enhanced sympathetic activity might play a pathogenic role in the transient myocardial dysfunction observed in SC.[7-9] However, the exact causative factors have not been fully elucidated. Despite the acute severity, complications are rare and the prognosis of patients with SC is generally considered favorable.[3-5]

Author Affiliations are listed at the end of this article.
Corresponding Author: Ingo Eitel, MD, University of Leipzig–Heart Center, Department of Internal Medicine/Cardiology, Strümpellstrasse 39, 04289 Leipzig, Germany (ingoeitel@gmx.de).

©2011 American Medical Association. All rights reserved.

Downloaded From: http://jama.jamanetwork.com/ on 05/20/2013

Cardiovascular magnetic resonance (CMR) imaging is uniquely suited for the evaluation of patients with SC. In addition to accurate visualization of regional wall motion abnormalities, it allows for precise quantification of right ventricular (RV) and LV function and the assessment of additional abnormalities (eg, pericardial and pleural effusion, LV and RV thrombi). Importantly, CMR imaging also provides markers for reversible (inflammation, ischemic edema) and irreversible (necrosis/fibrosis) injury, which may be particularly important to verify SC and exclude similar acute cardiac diseases such as myocardial infarction or myocarditis.[2,3,10-12]

Although various aspects of the natural history and clinical profile of SC have been described by several investigators in small, single-center populations,[3,13-15] multicenter data are lacking. The aim of our study was to comprehensively define the clinical spectrum and evolution of SC, including tissue characteristics, in a large, multicenter population from Europe and North America using a comprehensive, state-of-the-art CMR imaging protocol. A secondary objective was to explore the utility of a set of CMR criteria that might aid in diagnostic decision making in suspected SC.

METHODS

Patients and Inclusion Criteria

This prospective study was conducted at 7 tertiary care centers in Europe and North America between January 2005 and October 2010 (eAppendix; available at http://www.jama.com). All participants were consecutive patients at these centers and were entered in the study at the time of initial hospitalization. At acute presentation, all patients underwent a diagnostic workup/evaluation including electrocardiogram (ECG), transthoracic echocardiogram, blood sample analysis, coronary angiogram, and ventriculogram, as well as CMR imaging if no contraindications were present. The study protocol was approved by local ethics committees and all patients provided written informed consent to the CMR imaging. The diagnosis of SC was defined through clinical consensus based on fulfilling the following criteria: (1) an acute cardiac event typically presenting with chest pain and/or dyspnea; (2) transient systolic dysfunction with marked LV contraction abnormality (akinesia or dyskinesia of the LV apical and/or midventricular or basal segments) extending beyond a single coronary perfusion bed; (3) absence of significant (>50%) obstructive coronary artery disease or angiographic evidence of acute plaque rupture; (4) new ECG abnormalities (either ST elevation or T-wave inversion) or modest elevation in cardiac troponin level; (5) absence of pheochromocytoma; and (6) absence of myocarditis or typical ischemic transmural late gadolinium enhancement (LGE) on CMR (if available). These criteria are part of the proposed Mayo criteria for diagnosis of SC.[5]

One to 6 months after the acute event, patients with suspected SC were readmitted for clinical (ECG and blood sample analysis) and CMR follow-up for diagnosis confirmation. Those who had no repeat CMR imaging (n=81 [34%]) were followed up with echocardiography to confirm complete recovery of LV dysfunction. Patients who died (as verified by telephone interview, direct contact with the treating physician, or contact with the local government registration) were included as having completed clinical follow-up.

Clinical, echocardiographic, angiographic, and follow-up data of the study population were extracted from medical records and based on patient interviews (eg, careful history taking for stressful events) using a standardized case report form. The CMR analyses were performed by blinded, experienced investigators in a CMR core laboratory that has proven excellent reproducibility and low interobserver and intraobserver variability.[16]

CMR Imaging Protocol

In 239 patients (93%), CMR imaging was performed shortly after admission. Image acquisition was performed on 1.5-T whole-body systems in all centers using a standardized CMR protocol (in Leipzig, Ulm, and Parma: Intera CV, Philips Medical Systems, Best, the Netherlands; in Calgary, Berlin, and Rome: Avanto, Siemens Medical Solutions, Erlangen, Germany; and in Hamburg: Achieva, Philips Medical Systems). The standard protocol included steady state–free precession images for assessment of LV and RV function and regional wall motion abnormalities as well as LGE images for necrosis/fibrosis detection. In 199 patients (79%), T2-weighted images and/or early enhancement images were additionally acquired for assessment of myocardial edema and inflammation.[11,12,17] For edema imaging, a triple inversion recovery fast-spin echo sequence (short-TI inversion recovery) was used in contiguous short-axis views of the left ventricle. T1-weighted turbo spin echo images were acquired prior to and during the first 3 minutes after an intravenous bolus of 0.1 mmol/kg of gadolinium-based contrast agent for the assessment of the early gadolinium enhancement (EGE) ratio.[18] Late gadolinium enhancement images covering the entire LV were acquired approximately 10 to 15 minutes after intravenous administration of a second bolus of gadolinium–diethylenetriamine penta-acetic acid (DTPA) (0.1 mmol/kg). In case no EGE imaging was performed, LGE images were acquired approximately 10 to 15 minutes after intravenous administration of 0.2 mmol/kg of gadolinium-DTPA. A breath-hold 3-dimensional (Achieva and Intera CV, Phillips Medical Systems) or 2-dimensional (Avanto, Siemens Medical Solutions) inversion recovery gradient echo pulse sequence was used for LGE image acquisition. Inversion times were individually adjusted to optimize nulling of apparently normal myocardium (typical values, 200-300 milliseconds).

Image Evaluation

Offline image analysis was performed using certified CMR evaluation soft-

 ©2011 American Medical Association. All rights reserved.

Downloaded From: http://jama.jamanetwork.com/ on 05/20/2013

ware (cmr[42], Circle Cardiovascular Imaging Inc, Calgary, Alberta, Canada). Standard methods of LV functional analysis were performed by manually tracing endocardial and epicardial contours in the short-axis views. For assessment of myocardial edema in T2-weighted images, the ratio of mean signal intensity (SI) of the myocardium compared with that of the skeletal muscle was used (T2 SI ratio[12,17]). The EGE ratio, reflecting hyperemia and capillary leakage, was calculated as previously described.[12,17] Cardiovascular magnetic resonance findings were classified as consistent with myocardial inflammation if at least 2 of the following 3 criteria were present: (1) T2 SI ratio of at least 1.9; (2) EGE ratio of at least 4; and (3) nonischemic fibrosis (Lake Louise consensus criteria for the CMR diagnosis of myocardial inflammation).[17]

Late gadolinium enhancement images were assessed qualitatively and quantitatively. For quantitative assessment, a region of interest was traced in an apparently normal (ie, low-SI) area for defining normal myocardium. An automated computer-aided threshold detection set at 3 and 5 SDs (5 SDs represents the cutoff for fibrosis detection in acute myocardial infarction and myocarditis) above the mean SI of apparently normal myocardium was used to identify regions of myocardial necrosis/fibrosis in LGE images.[19]

Statistical Analysis

Categorical variables are expressed as number and percentage of patients. Continuous data are estimated as mean (SD) or as median and interquartile range (IQR) for nonnormally distributed data. Differences between groups were assessed using the 2-tailed Fisher exact test or the χ^2 test for categorical variables and using the *t* test for continuous data with normal distribution. Otherwise, the nonparametric Wilcoxon rank sum test was used. Differences between paired samples (ie, comparisons of CMR results for patients with SC at baseline and follow-up) were assessed using the McNemar test for categorical paired data and the paired *t* test for continuous data with normal distribution. Otherwise, the nonparametric Wilcoxon matched-pairs test was used. Subgroup comparisons were preplanned based on previously published literature. All statistical tests were performed with SPSS software, version 15.0 (SPSS Inc, Chicago, Illinois). A 2-tailed $P<.05$ was considered statistically significant.

RESULTS

Between January 2005 and October 2010, 256 patients fulfilling the diagnostic criteria for SC were enrolled. Of these, 239 (93%) underwent a comprehensive CMR examination. Reasons for not undergoing CMR are shown in FIGURE 1. Among all patients, a clinical follow-up for diagnosis confirmation (complete recovery of LV dysfunction) was performed. Of these, 158 (62%) additionally underwent a CMR follow-up examination (Figure 1).

Figure 1. Study Flow

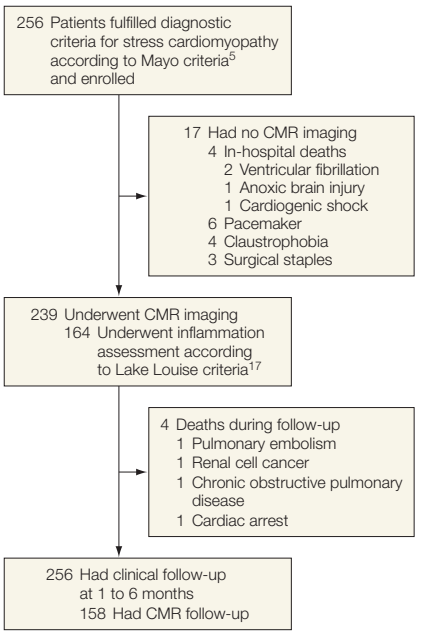

CMR indicates cardiovascular magnetic resonance imaging.

Presentation and Triggers

Patients with SC were a mean of 69 (SD, 12) years old (range, 30-90 years); 89% (n=227) were women, most commonly (81% [n=207]) postmenopausal (aged >50 years). Twenty women (8%) were aged 50 years or younger. Men accounted for 11% of cases (n=29) (TABLE 1). There were no age differences between men and women ($P=.64$).

At presentation, 225 patients (88%) reported symptoms consistent with ACS (Table 1). A limited number of patients were admitted because of other symptoms; specifically, syncope (n=9 [4%]) and asystole (n=3; [1%]). The remaining 19 patients (7%) were admitted for suspected ACS as identified during management or monitoring of noncardiac conditions (eg, medical/surgical procedures or diagnostic tests) with new ECG abnormalities, acute onset of chest pain, and/or positive troponin levels.

In 182 patients (71%), a significant stressful event less than 48 hours before presentation could be identified. Triggering conditions were emotional stress in 77 (30%) and physical stress in 105 (41%) (TABLE 2).

No differences in baseline characteristics and clinical presentation were observed across centers.

ECG and Biomarkers

At presentation, ECGs showed abnormalities in 222 patients (87%). Frequencies of specific ECG findings are listed in Table 1. The initial troponin T level was (typically only mildly) increased in 231 patients (90%). No relation was evident between ballooning patterns (typical apical ballooning vs midventricular or basal ballooning) and troponin levels (0.4 [IQR, 0.2-1.2] ng/mL vs 0.4 [IQR, 0.1-0.7] ng/mL; $P=.12$) as well as clinical features (eg, age, sex, stress trigger).

Coronary Angiography

All 256 patients underwent cardiac catheterization. Left ventriculography revealed typical apical ballooning in 210 (82%), midventricular ballooning in 44 (17%), and an inverted, basal pattern

©2011 American Medical Association. All rights reserved.

Downloaded From: http://jama.jamanetwork.com/ on 05/20/2013

in 2 (1%). Coronary angiography showed healthy coronary arteries in 193 patients (75%), whereas in 16 patients (6%), an epicardial coronary artery stenosis of 75% or more was observed (right coronary artery, n=12; diagonal coronary artery, n=2; left circumflex coronary artery, n=2) that did not correspond to the area of wall motion abnormality. The remaining 47 patients (18%) had only mild coronary atherosclerosis (<50% luminal diameter stenosis). No coronary lesions had angiographic features of acute plaque rupture. Two patients (1%) had spontaneous coronary spasm.

CMR Imaging

Cardiovascular magnetic resonance imaging was performed a median of 3 days (IQR, 2-4 days) after hospital admission. Cine imaging confirmed the detected ballooning patterns (FIGURE 2; see interactive CMR cine imaging of the ballooning patterns at http://www.jama.com; TABLE 3), with moderate to severe reduction of LV function in all patients (mean LV ejection fraction, 47.7% [SD, 11.1%]; 95% confidence interval [CI], 47.1%-50.3%). Biventricular ballooning (Figure 2D) was observed in 81 patients (34%). Interestingly, LV ejection fraction was lower than in patients without RV involvement (mean, 43.1% [SD, 8.5%]; 95% CI, 41.0%-45.3% vs mean, 48.2% [SD, 9.4%]; 95% CI, 46.2%-49.6%; $P<.001$). Additionally, patients with biventricular ballooning were older (mean, 73.4 [SD, 12.1] years; 95% CI, 70.2-76.3 years vs mean, 66.5 [SD, 11.2] years; 95% CI, 64.4-68.5 years; $P<.001$), had significantly more frequent preceding stressful events (86 vs 65%; $P=.01$), and showed a trend for longer hospital stays (mean, 7 [SD, 5] days; 95% CI, 6-8 days vs mean, 5 [SD, 3] days; 95% CI, 5-6 days; $P=.07$).

Myocardial edema was visible in 162 of 199 patients (81%) with a distinct transmural, midventricular to apical regional distribution pattern matching the distribution of LV dysfunction (FIGURE 3). Focal or patchy LGE was detected in 22 patients (9%) when using a threshold of 3 SD instead of 5 SD above the mean of remote myocardium to define significant enhancement, albeit with an SI difference lower than typically observed in myocardial infarction. When using an SI threshold of 5 SD, none of the patients had evidence of LGE (FIGURE 4). Patients with such minor LGE had significantly higher troponin levels at presentation (0.6 [IQR, 0.3-1.7] ng/mL vs 0.4 [IQR, 0.1-1.0] ng/mL; $P=.002$), while LV ejection fraction (LGE positive, 47.5% [SD, 9.6%] vs LGE negative, 47.9% [SD, 11.2%]; $P=.94$), end-diastolic volume ($P=.78$), and end-systolic volume ($P=.72$) did not differ between LGE-positive and LGE-negative groups. No relation was evident between the occurrence of LGE and clinical presentation, mortality, age, sex, ECG pattern, or type of stress trigger.

A total of 164 patients underwent all 3 CMR protocol components required to assess the Lake Louise consensus criteria for myocardial inflammation (T2 SI ratio, EGE ratio, and LGE). Of these patients, 110 (67%) were positive for acute myocardial inflammation, with increased values for the T2 SI ratio and the EGE ratio during the acute phase (TABLE 4).

Table 1. Clinical Characteristics (n = 256)

Characteristics	No. (%) of Participants[a]
Age, mean (SD), y	
All	69 (12)
Women	69 (12)
Men	70 (10)
Female	227 (89)
Coronary risk factors	
Hypertension	187 (73)
Hyperlipidemia	66 (26)
Diabetes	49 (19)
Smoking	50 (20)
Overweight (BMI 25-30)	130 (51)
Obese (BMI >30)	48 (19)
BMI, mean (SD)	26 (5)
Clinical presentation	
Chest pain and/or dyspnea	225 (88)
Syncope	9 (4)
Asystole	3 (1)
Pre-/peri-/postmedical/surgical procedure (with electrocardiographic abnormality, chest pain)	19 (7)
Elevated troponin T (cutoff, 0.1 ng/mL)	231 (90)
Maximal troponin T, median (IQR), ng/mL	0.4 (0.1-1.0)
Elevated CK (cutoff, 192 U/L)	134 (52)
Maximal CK at admission, median (IQR), U/L	174 (96-276)
Elevated CK myocardial band (cutoff, 24 U/L)	162 (63)
Maximal CK myocardial band, median (IQR), U/L	24 (18-42)
Electrocardiographic changes at presentation	222 (87)
ST elevation	108 (42)
T-wave inversion	96 (38)
ST depression	4 (2)
New left bundle-branch block	2 (1)
High-degree atrioventricular block	3 (1)
Asystole	3 (1)
Pacemaker electrocardiogram	6 (2)

Abbreviations: BMI, body mass index (calculated as weight in kilograms divided by height in meters squared); CK, creatine kinase; IQR, interquartile range.
[a] Data are presented as No. (%) of participants unless otherwise indicated.

©2011 American Medical Association. All rights reserved.

Downloaded From: http://jama.jamanetwork.com/ on 05/20/2013

Additional CMR Findings

In 33% of patients, pleural effusion was observed, significantly more often in patients with biventricular ballooning (62% vs 19%; $P < .001$) (Figure 2D, asterisk). Pericardial effusion was detected in 102 patients (43%) (Figure 2A, asterisk). Interestingly, it was more frequently observed (74%) in patients with CMR evidence of myocardial inflammation. Left ventricular thrombi were identified in 4 patients (2%).

Acute Management

Initially, most patients were treated using standard cardiovascular medications for ACS (acetylsalicylic acid, clopidogrel, heparin, β-blockers, angiotensin-converting enzyme inhibitors, vasodilators, and diuretics). After exclusion of coronary artery stenosis, the patients received standard supportive care for congestive heart failure with β-blockers, angiotensin-converting enzyme inhibitors/angiotensin II receptor blockers, diuretics, and aldosterone antagonists. In 7 patients (3%) with severe hemodynamic compromise, an intra-aortic balloon pump was implanted. All patients with thrombi (n=4[2%]) were treated with warfarin with no subsequent events.

In-Hospital Survival

Four patients (3 women and 1 man) died in the hospital because of ventricular fibrillation (n=2), cardiogenic shock (n=1), and hypoxic brain injury (n=1). Of these, 3 patients had apical and 1 patient had midventricular ballooning. No relation was evident between in-hospital outcome and ECG pattern, troponin level, or clinical features.

Follow-up

Another 4 patients died during the follow-up period (Figure 1). Among the remaining 248 patients, a complete clinical follow-up including CMR imaging and/or echocardiography for confirmation of LV function recovery was available. Cardiovascular magnetic resonance imaging was performed in 158 patients (62%) after a median of 97 (IQR, 36-123) days. Follow-up echocardiography and CMR imaging showed normalization of LV ejection fraction in all patients (Figure 2). Similarly, end-diastolic and end-systolic volume decreased (Table 3). Furthermore, mean T2 SI and EGE ratios decreased significantly. Using a threshold of 5 SD, none of the patients had LGE at follow-up. No relation was evident between persistence of tissue characteristics on CMR imaging and clinical features, troponin level, or type of stress trigger.

Table 2. Preceding Stressful Events

Events	No. (%) of Participants
Emotional stressors	77 (30)
Death of a relative/friend/pet	20
Interpersonal conflict	15
Panic/fear/anxiety	10
Anger/frustration	6
Job problems	5
Severe disease of a relative/friend	4
Diagnosis of malignancy	4
Bad news	3
Other	10
Physical stressors	105 (41)
Perisurgical or postsurgical	23
Acute respiratory failure (eg, chronic obstructive pulmonary disease, asthma bronchiale)	19
Malignancy/chemotherapy	8
Abdominal pain/gastric ulcera/diverticulitis	8
Infection	6
Stroke	4
Administration of exogenous catecholamines	4
Allergic drug/vaccination reaction	3
Colonoscopy	2
Seizure	2
Fall	2
Other	24
No identifiable stressors	74 (29)

COMMENT

Our study allowed for several important observations: first, we found a considerably broader clinical profile than previously reported. Second, myocardial edema, inflammation, and absence of fibrosis have been identified as potentially important markers for diffuse, reversible myocardial injury and provide unique insights into the pathogenesis and tissue pathology of this increasingly recognized syndrome. Third, our data indicate that CMR imaging using specific criteria may be useful as a diagnostic tool for patients with SC at the time of acute clinical presentation.

Clinical Characteristics and Presentation

Our multicenter data confirm the data from previous reports.[3,13-15] Typically, SC affects postmenopausal women after they experience a stressful event and it mimics ACS with symptoms of chest pain and/or dyspnea (n=225 [88%]), ischemia-like ECG changes (n=222 [87%]), and a slight increase in cardiac biomarkers (n=231 [90%]). However, our results indicate that a broader clinical profile may be encountered in these patients. In contrast to previous studies, we found a significant percentage of men (n=29 [11%]) and younger, often premenopausal women (n=20 [8%] aged ≤50 years and n=44 [17%] aged ≤55 years). Furthermore, despite

©2011 American Medical Association. All rights reserved.

Downloaded From: http://jama.jamanetwork.com/ on 05/20/2013

Figure 2. Cardiovascular Magnetic Resonance (CMR) Images of 4 Distinct Ballooning Patterns in Stress Cardiomyopathy and at 3-Month Follow-up

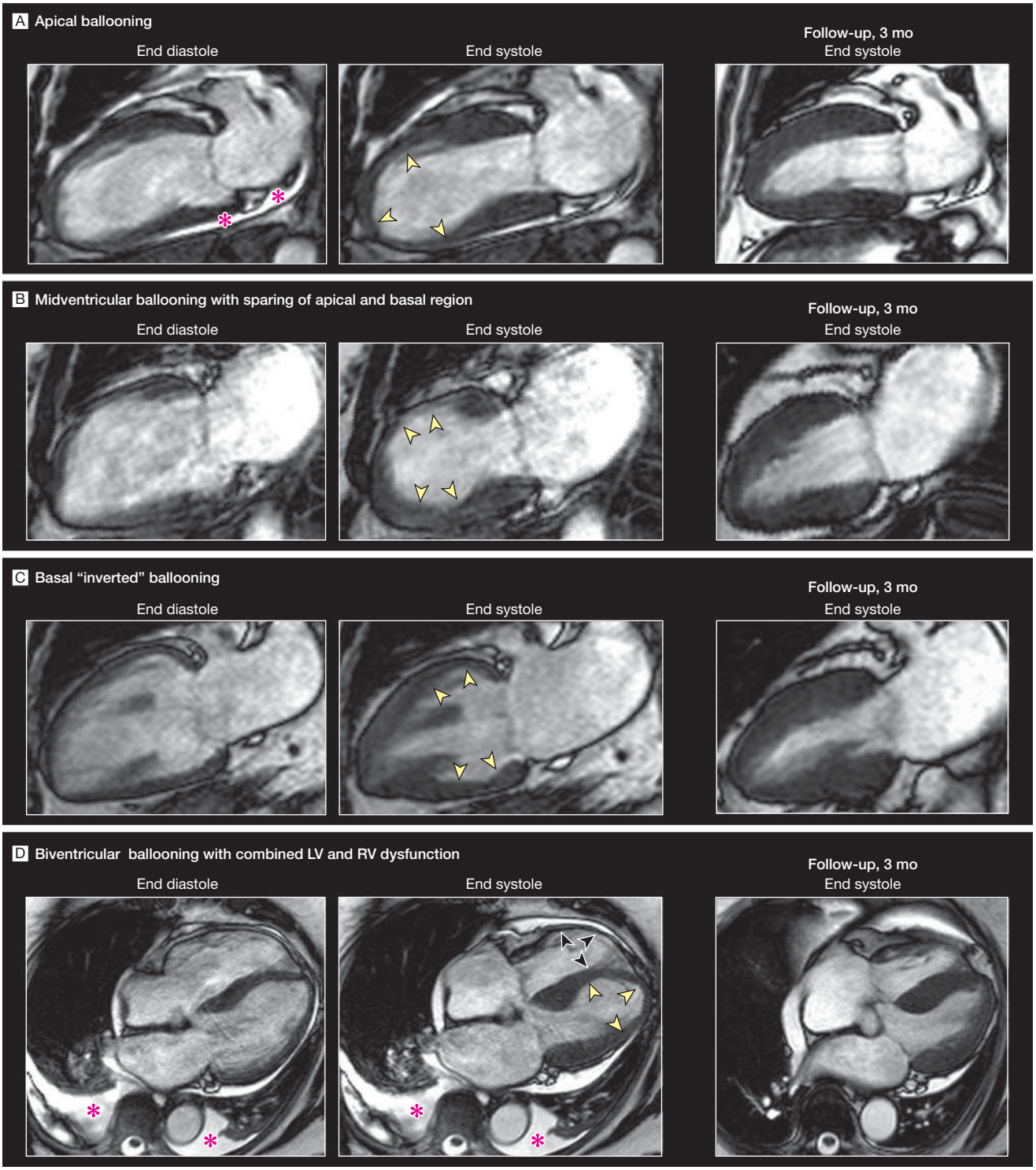

Images for each ballooning pattern are representative examples from a patient included in the study. A-C, Vertical long-axis views. A (left panel), asterisks indicate pericardial effusion. Middle panel, yellow arrowheads indicate the area of apical akinesia. B (middle panel), yellow arrowheads indicate the area of mid left ventricular (LV) akinesia. C (middle panel), yellow arrowheads indicate the area of basal akinesia. D, Horizontal long-axis view. Asterisks indicate bilateral pleural effusion at acute presentation. Middle panel, yellow arrowheads indicate apical LV akinesia and black arrowheads indicate right ventricular (RV) apical akinesia. See interactive CMR cine imaging of the ballooning patterns at http://www.jama.com.

 ©2011 American Medical Association. All rights reserved.

Downloaded From: http://jama.jamanetwork.com/ on 05/20/2013

Table 3. Cardiovascular Magnetic Resonance (CMR) Imaging Characteristics at Acute Presentation and Follow-up[a]

Characteristics	Baseline (n = 239)	Baseline With No Follow-up (n = 81)	Baseline With Follow-up (n = 158)	Follow-up (n = 158)
Ballooning pattern, No. (%)				
Apical	197 (82)	68 (84)	129 (82)	0
Midventricular	40 (17)	11 (14)	29 (18)	0
Basal	2 (1)	1 (1)	1 (1)	0
Biventricular	81 (34)	21 (26)	60 (38)	0
LV ejection fraction, mean (SD) [95% CI], %	47.7 (11.1) [47.1-50.3]	48.8 (12.1) [47.4-51.2]	47.5 (9.6) [45.9-49.7]	66.3 (6.6) [64.1-68.2]
LV end-diastolic volume, mean (SD) [95% CI], mL	133.9 (28.9) [129.5-138.3]	131.5 (28.2) [125.1-137.9]	135.5 (29.3) [130.4-140.6]	118.2 (25.2) [113.0-123.2]
LV end-systolic volume, mean (SD) [95% CI], mL	68.8 (22.4) [65.0-72.3]	67.1 (21.7) [61.8-71.5]	70.3 (23.1) [65.3-73.4]	43.2 (15.0) [40.3-45.9]
Pleural effusion, No. (%)	79 (33)	23 (28)	56 (35)	1 (2)
Pericardial effusion, No. (%)	102 (43)	30 (37)	72 (46)	4 (2)
Thrombi, No. (%)	4 (2)	0	4 (3)	0

Abbreviations: CI, confidence interval; LV, left ventricular.
[a]Comparisons between baseline and follow-up CMR results were performed only in patients with both CMR scans (at acute presentation and at follow-up). $P<.001$ for all comparisons.

careful history taking, only two-thirds of patients had a clearly identifiable preceding stressor, whereas in previous reports the percentage with preceding emotional or physical triggers was as high as 89%.[3] Thus, our large multicenter cohort demonstrates that the absence of an identifiable stressful event does not rule out the diagnosis, and, hence, precipitating mechanisms may be more complex, such as involvement of vascular, endocrine, and central nervous systems. Such clinical heterogeneity could contribute to ambiguity in the recognition of SC and thereby affect potential management strategies. Consequently, enhanced awareness and recognition of a broad clinical profile of SC as demonstrated in the current study is mandatory for correct diagnosis and treatment among patients with suspected SC.

Figure 3. Cardiovascular Magnetic Resonance Identification of Myocardial Edema in a Representative Patient With Stress Cardiomyopathy

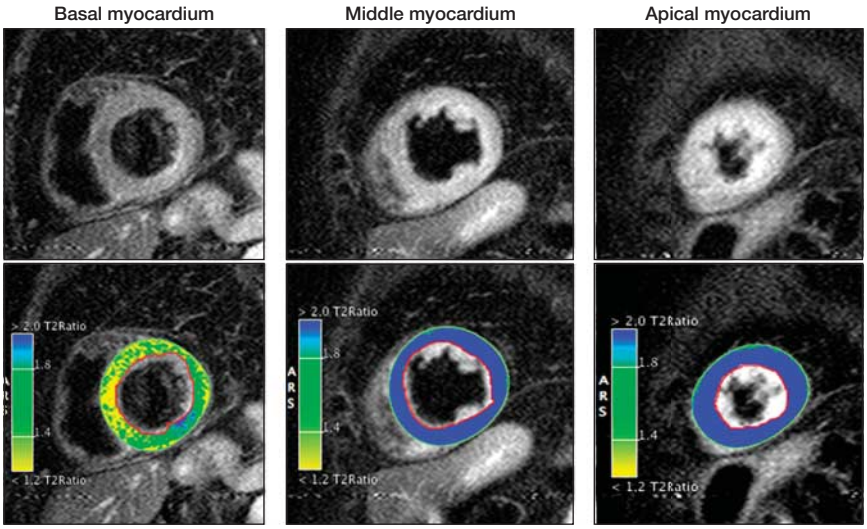

T2-weighted images (short-axis view) demonstrating normal signal intensity (SI) of the basal myocardium but global edema of the mid and apical myocardium. Computer-aided SI analysis (bottom row) of the T2-weighted images with color-coded display of relative SI normalized to skeletal muscle (blue indicates an SI ratio of myocardium to skeletal muscle of ≥1.9 or higher, indicating edema; green/yellow indicates a normal SI ratio of <1.9) confirm the presence of global mid and apical edema. Outlines of regions of interest are manually drawn around the myocardium (red contour=subendocardial border; green contour=subepicardial border) and within the skeletal muscle (contour not shown).

Ballooning Patterns

We observed a diversity of contraction patterns during the acute phase of SC, including apical, mid-ventricular, basal, and biventricular ballooning. Most commonly, the typical apical ballooning shape with akinesis of apical and midventricular LV segments was present. However, 17% of patients (n=40) presented with a midventricular variant with apical sparing and 2 patients (1%) with isolated basal ballooning. Since the initial description, the number of reports of apical sparing patterns in patients with SC is increasing.[4,18,20] It is still unclear why there are different patterns of regional distribution of wall motion abnormalities. In our study and other studies, there are no apparent clinical differences between the different regional forms of transient ballooning. It has been suggested that the variations in regional wall motion mainly relate to differences in the anatomic location of cardiac adrenergic receptors and/or β-ad-

©2011 American Medical Association. All rights reserved.

Downloaded From: http://jama.jamanetwork.com/ on 05/20/2013

renergic receptor polymorphisms, the degree of excess sympathetic activity involved, and/or interindividually differing susceptibilities to such sympathetic stimulation.[21,22]

Use of CMR imaging allowed us to clarify the exact incidence of biventricular ballooning in our large patient cohort. We observed RV involvement in 34% of patients (n=81) and found an association with longer hospitalization, markers of heart failure (as reflected by a lower LV ejection fraction and a high incidence of bilateral pleural effusions), and older age. Consequently, biventricular ballooning may portend a longer and more severe course of the disease compared with patients with isolated LV involvement. This finding is consistent with previous studies.[10] Clinicians should be aware of the possibility of RV dysfunction because it might have a significant effect on patient morbidity, treatment, and outcome.

CMR Characteristics and Pathophysiological Considerations

Cardiovascular magnetic resonance imaging has the unique ability to characterize various pathophysiological effects of reversible and irreversible acute myocardial injury (edema, hyperemia, and necrosis/fibrosis) and contributes to our understanding and differential diagnosis of this entity.[2,12,23] So far, various CMR criteria have been used in rather small populations.[2,24] Based on published data and our study, the largest CMR imaging series to date, we identified the following strong diagnostic criteria for SC that will require validation in other populations: (1) severe LV dysfunction in a noncoronary regional distribution pattern; (2) myocardial edema colocated with the regional wall motion abnormality (edema should be verified by a quantitative SI

Figure 4. Cardiovascular Magnetic Resonance Identification of Necrosis/Fibrosis in a Representative Patient With Stress Cardiomyopathy

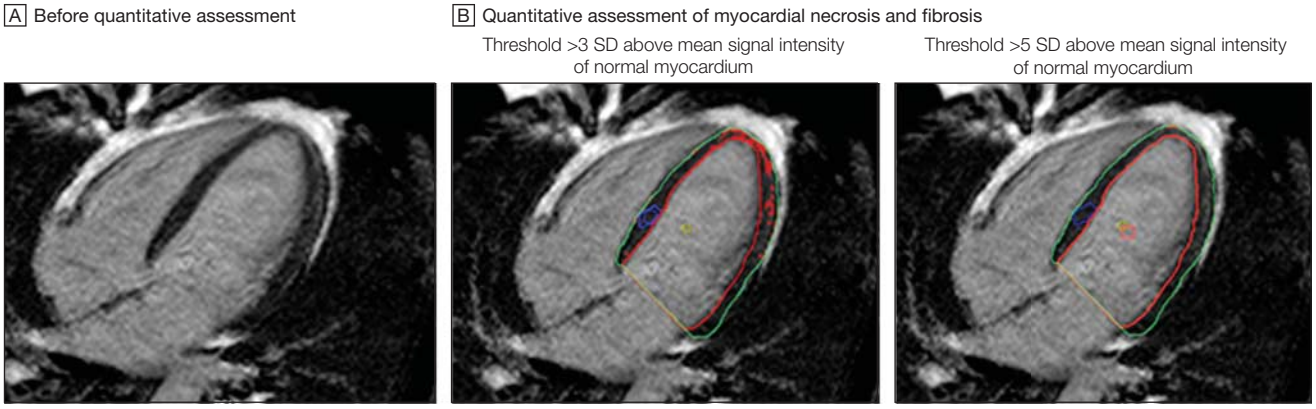

Myocardial fibrosis was quantified, B, by selecting a region of interest in nonenhancing healthy myocardium (blue contour) and setting automated computer detection to 3 SDs (left) and 5 SDs (right) above the mean of healthy myocardium to identify fibrosis. Computer-aided signal intensity analysis detected positive late gadolinium enhancement (LGE) more than 3 SDs above the mean (red overlay), but no significant LGE more than 5 SDs above the mean was present (red contour=subendocardial border; green contour=subepicardial border of the myocardium).

Table 4. Cardiovascular Magnetic Resonance Imaging Tissue Characteristics at Acute Presentation and Follow-up[a]

Characteristics	Baseline (n = 199)	Baseline With No Follow-up (n = 60)	Baseline With Follow-up (n = 139)	Follow-up (n = 139)
Focal edema, No. (%)[b]	162 (81)	45 (75)	117 (84)	2 (1)
Elevated T2 SI ratio, No. (%)[b]	169 (85)	49 (82)	120 (86)	4 (3)
T2 SI ratio, mean (SD) [95% CI] (cutoff level, ≥1.9)	2.3 (0.5) [2.2.-2.4]	2.3 (0.5) [2.1-2.4]	2.4 (0.5) [2.3-2.5]	1.7 (0.3) [1.6-1.8]
Elevated EGE ratio, No. (%)[c]	114 (70)	28 (72)	86 (69)	6 (5)
EGE ratio, mean (SD) [95% CI] (cutoff level, ≥4)	5.5 (3.1) [5.0-6.1]	5.2 (2.7) [4.4-6.0]	5.8 (3.3) [5.0-6.5]	3.3 (1.3) [2.9-3.6]
Elevated EGE ratio and T2 SI ratio, No. (%)[c]	110 (67)	27 (69)	83 (66)	2 (2)
Any LGE, No. (%)[d]	22 (9)	1 (1)	21 (13)	1 (1)
LGE >5 SD, No. (%)[d]	0	0	0	0

Abbreviations: CI, confidence interval; EGE, early gadolinium enhancement; LGE, late gadolinium enhancement; SI, signal intensity.
[a] $P<.001$ for all comparisons.
[b] Assessed in 199 patients (79%) at acute phase and 139 patients at follow-up.
[c] Assessed in 164 patients (64%) at acute phase and 125 patients at follow-up.
[d] Assessed in 239 patients (93%) at acute phase and 158 patients at follow-up.

 ©2011 American Medical Association. All rights reserved.

Downloaded From: http://jama.jamanetwork.com/ on 05/20/2013

analysis, best by calculating the SI ratio between myocardium and skeletal muscle [T2 SI ratio]; a cutoff value of ≥1.9 should be used to define edema); (3) absence of high-signal areas in LGE images (a cutoff value of >5 SD should be used to define significance); and (4) increased early myocardial gadolinium uptake (increased uptake is defined by an early EGE ratio ≥4.0 [optimal cutoff values may vary between scanners]). The confirmative criterion (with >4-week follow-up) for all diagnostic criteria is complete or near-complete resolution.

The absence of LGE has been described in many cases[2,3,10,12] and is a common diagnostic criterion in most CMR imaging centers. However, a recent publication demonstrated that subtle fibrosis (LGE) may be seen in patients with SC.[24] Indeed, 22 of 239 patients (9%) in our study showed minute focal or patchy nonischemic myocardial scarring. When compared with acute myocardial infarction, the SI was much lower and the extent of LGE was smaller.[17,23] In fact, with a cutoff value of 5 SD[19] for necrosis/fibrosis detection, none of the SC patients had evidence of LGE. Thus, the absence of significant LGE (>5 SD) combined with myocardial edema and marked LV ballooning is a unique feature of SC. Importantly, the presence of less rigorously defined (threshold of 3 SD above remote mean SI) LGE during the acute phase had no persisting effect on global LV function, and there was no evidence of LGE at CMR follow-up. This recovery is consistent with the benign prognosis of SC, as visually apparent LGE is associated with a poorer prognosis in both ischemic and nonischemic cardiomyopathies.[25,26] Moreover, the absence of significant LGE is consistent with the complete normalization of LV function observed in patients with SC.

As a novel marker, in the majority of patients (n=162 [70%]), myocardial edema was present in the regions with abnormal systolic function (Figure 3). Edema is an important diagnostic target for assessing the acuity, extent, and severity of tissue damage in vivo. The exact pathophysiological mechanisms underlying the development of myocardial edema in SC remain unclear but inflammation, increased LV wall stress, and/or transient ischemia appear pivotal. High intraventricular pressure may precipitate perfusion abnormalities and—even in the absence of coronary artery stenosis—focal myocardial ischemia. The observed injury (edema), however, was not more pronounced in subendocardial layers. The very uniform regional distribution of edema differs from the typical patterns observed in myocarditis with their often subepicardial and inferolateral preference (Figure 3).[18]

Cardiovascular magnetic resonance imaging has also emerged as a leading diagnostic tool for assessment of myocardial inflammation.[17] Hallmark changes in inflammation include myocardial hyperemia or capillary leakage, edema, and fibrosis, all of which can be noninvasively visualized using CMR imaging. In our study, 67% of patients who underwent inflammation assessment according to the Lake Louise consensus criteria for the CMR diagnosis of myocardial inflammation/myocarditis had evidence of active inflammation. Of these, 75% had concomitant pericardial effusion, providing supportive evidence of an inflammatory process in the acute phase. Consequently, our results strengthen the concept of an inflammatory process playing a role in the acute setting of SC. However, the precise contribution of myocardial inflammation to LV dysfunction in SC is unclear, and it remains to be established whether inflammation is a direct cause of the syndrome or a secondary phenomenon due to sympathetic overdrive and/or microvascular ischemia.

Strong evidence exists that enhanced sympathetic activity might play a central pathogenic role in transient myocardial dysfunction in patients with SC.[7-9] However, neither elevation in circulating catecholamines nor contraction band necrosis, a feature of catecholamine toxicity in endomyocardial biopsies, has had consistent findings.[27] Moreover, as shown by the current study and others, preceding stress is not evident in every case, and it would therefore seem inappropriate to assume a common trigger among all SC patients. Thus, additional hypotheses are required to explain the phenomenon, and SC may be caused by more than 1 etiology. Aborted myocardial infarction and plaque rupture have been recently excluded as underlying cause.[28] Likewise, LV outflow tract obstruction and coronary vasospasms are not strongly supported in the literature or by our study results, despite isolated reports.[4,5]

Thus, the exact pathophysiology of SC is still not established but is likely multifactorial, involving the vascular (abnormal vasoreactivity, endothelial and microvascular dysfunction), endocrine (sex differences, reduced estrogen levels), and central nervous (abnormal response to stressful events) systems. At the tissue level, myocardial edema as a sign of acute but reversible injury and diffuse inflammation in the absence of significant necrosis/fibrosis are characteristic of SC.

CONCLUSION

The clinical profile of SC is broader than reported previously, including younger patients, men, and patients without an identifiable stressful trigger. Cardiovascular magnetic resonance imaging may provide incremental diagnostic information and could allow for verifying all relevant functional and tissue changes and therefore might contribute to the establishment of or rule out the diagnosis of SC at the time of acute clinical presentation. The combination of typical regional wall motion abnormalities, the presence of reversible myocardial injury, and the absence of significant irreversible tissue injury may serve as a very useful set of diagnostic criteria and should be prospectively tested.

Author Affiliations: Departments of Internal Medicine/Cardiology (Drs Eitel, Desch, Schuler, and Thiele) and Diagnostic and Interventional Radiology (Dr Gutberlet), Heart Center, University of Leipzig, Leipzig, Germany; Departments of Cardiac Sciences and Radiol-

©2011 American Medical Association. All rights reserved.

Downloaded From: http://jama.jamanetwork.com/ on 05/20/2013

ogy, Stephenson Cardiovascular Magnetic Resonance Centre at the Libin Cardiovascular Institute of Alberta, University of Calgary, Calgary, Canada (Drs Eitel, Carbone, Strohm, and Friedrich); Working Group of Cardiovascular Magnetic Resonance, Charité University Medicine Berlin, Experimental and Clinical Research Center, and Department of Cardiology and Nephrology, HELIOS Klinikum Berlin-Buch, Berlin, Germany (Drs von Knobelsdorff-Brenkenhoff and Schulz-Menger); Department of Internal Medicine II, University of Ulm, Ulm, Germany (Dr Bernhardt); Department of Radiological Sciences, University of Rome, Sapienza, Rome, Italy (Drs Carbone and Francone); Center for Cardiology and Cardiovascular Surgery, University of Hamburg-Eppendorf, Hamburg, Germany (Dr Muellerleile); and Division of Cardiology, Department of Heart and Lung, Azienda Ospedaliero University of Parma, Parma, Italy (Dr Aldrovandi).

Author Contributions: Dr Eitel had full access to all of the data in the study and takes responsibility for the integrity of the data and the accuracy of the data analysis. Drs Thiele and Friedrich share senior authorship of this article.
Study concept and design: Eitel, Thiele, Friedrich.
Acquisition of data: Eitel, von Knobelsdorff-Brenkenhoff, Bernhardt, Carbone, Muellerleile, Aldrovandi, Francone, Desch, Gutberlet, Strohm, Schuler, Schulz-Menger, Thiele, Friedrich.
Analysis and interpretation of data: Eitel, von Knobelsdorff-Brenkenhoff, Bernhardt, Carbone, Muellerleile, Aldrovandi, Francone, Desch, Gutberlet, Strohm, Schuler, Schulz-Menger, Thiele, Friedrich.
Drafting of the manuscript: Eitel.
Critical revision of the manuscript for important intellectual content: Eitel, von Knobelsdorff-Brenkenhoff, Bernhardt, Carbone, Muellerleile, Aldrovandi, Francone, Desch, Gutberlet, Strohm, Schuler, Schulz-Menger, Thiele, Friedrich.
Statistical analysis: Eitel, Desch.
Obtained funding: Eitel, Thiele.
Administrative, technical, or material support: Eitel, Thiele, Schuler, Friedrich.
Study supervision: Eitel, Schulz-Menger, Thiele, Friedrich.
Conflict of Interest Disclosures: All authors have completed and submitted the ICMJE Form for Disclosure of Potential Conflicts of Interest. Dr Friedrich reports that he is a shareholder of and consultant to Circle Cardiovascular Imaging Inc. No other disclosures were reported.
Funding/Support: Dr Eitel is supported by a research grant from the German Society of Cardiology.
Role of Sponsor: The German Society of Cardiology had no role in the design and conduct of the study; in the collection, analysis, and interpretation of the data; or in the preparation, review, or approval of the manuscript.
Online-Only Material: Interactive CMR cine imaging of the ballooning patterns and the eAppendix are available at http://www.jama.com.

REFERENCES

1. Maron BJ, Towbin JA, Thiene G, et al; American Heart Association; Council on Clinical Cardiology, Heart Failure and Transplantation Committee; Quality of Care and Outcomes Research and Functional Genomics and Translational Biology Interdisciplinary Working Groups; Council on Epidemiology and Prevention. Contemporary definitions and classification of the cardiomyopathies: an American Heart Association Scientific Statement from the Council on Clinical Cardiology, Heart Failure and Transplantation Committee; Quality of Care and Outcomes Research and Functional Genomics and Translational Biology Interdisciplinary Working Groups; and Council on Epidemiology and Prevention. *Circulation*. 2006;113(14):1807-1816.
2. Eitel I, Behrendt F, Schindler K, et al. Differential diagnosis of suspected apical ballooning syndrome using contrast-enhanced magnetic resonance imaging. *Eur Heart J*. 2008;29(21):2651-2659.
3. Sharkey SW, Windenburg DC, Lesser JR, et al. Natural history and expansive clinical profile of stress (tako-tsubo) cardiomyopathy. *J Am Coll Cardiol*. 2010; 55(4):333-341.
4. Hurst RT, Prasad A, Askew JW III, Sengupta PP, Tajik AJ. Takotsubo cardiomyopathy: a unique cardiomyopathy with variable ventricular morphology. *JACC Cardiovasc Imaging*. 2010;3(6):641-649.
5. Prasad A, Lerman A, Rihal CS. Apical ballooning syndrome (tako-tsubo or stress cardiomyopathy): a mimic of acute myocardial infarction. *Am Heart J*. 2008; 155(3):408-417.
6. Anderson JL, Adams CD, Antman EM, et al; American College of Cardiology; American Heart Association Task Force on Practice Guidelines (Writing Committee to Revise the 2002 Guidelines for the Management of Patients With Unstable Angina/Non-ST-Elevation Myocardial Infarction); American College of Emergency Physicians; Society for Cardiovascular Angiography and Interventions; Society of Thoracic Surgeons; American Association of Cardiovascular and Pulmonary Rehabilitation; Society for Academic Emergency Medicine. ACC/AHA 2007 guidelines for the management of patients with unstable angina/non-ST-elevation myocardial infarction: a report of the American College of Cardiology/American Heart Association Task Force on Practice Guidelines (Writing Committee to Revise the 2002 Guidelines for the Management of Patients With Unstable Angina/Non-ST-Elevation Myocardial Infarction) developed in collaboration with the American College of Emergency Physicians, the Society for Cardiovascular Angiography and Interventions, and the Society of Thoracic Surgeons endorsed by the American Association of Cardiovascular and Pulmonary Rehabilitation and the Society for Academic Emergency Medicine. *J Am Coll Cardiol*. 2007;50(7): e1-e157.
7. Wittstein IS, Thiemann DR, Lima JA, et al. Neurohumoral features of myocardial stunning due to sudden emotional stress. *N Engl J Med*. 2005;352 (6):539-548.
8. Abraham J, Mudd JO, Kapur NK, Klein K, Champion HC, Wittstein IS. Stress cardiomyopathy after intravenous administration of catecholamines and β-receptor agonists. *J Am Coll Cardiol*. 2009;53(15): 1320-1325.
9. Watanabe H, Kodama M, Okura Y, et al. Impact of earthquakes on takotsubo cardiomyopathy. *JAMA*. 2005;294(3):305-307.
10. Haghi D, Athanasiadis A, Papavassiliu T, et al. Right ventricular involvement in takotsubo cardiomyopathy. *Eur Heart J*. 2006;27(20):2433-2439.
11. Abdel-Aty H, Cocker M, Friedrich MG. Myocardial edema is a feature of tako-tsubo cardiomyopathy and is related to the severity of systolic dysfunction: insights from T2-weighted cardiovascular magnetic resonance. *Int J Cardiol*. 2009;132(2): 291-293.
12. Eitel I, Lücke C, Grothoff M, et al. Inflammation in takotsubo cardiomyopathy: insights from cardiovascular magnetic resonance imaging. *Eur Radiol*. 2010; 20(2):422-431.
13. Athanasiadis A, Vogelsberg H, Hauer B, Meinhardt G, Hill S, Sechtem U. Transient left ventricular dysfunction with apical ballooning (tako-tsubo cardiomyopathy) in Germany. *Clin Res Cardiol*. 2006; 95(6):321-328.
14. Eshtehardi P, Koestner SC, Adorjan P, et al. Transient apical ballooning syndrome—clinical characteristics, ballooning pattern, and long-term follow-up in a Swiss population. *Int J Cardiol*. 2009;135(3): 370-375.
15. Singh NK, Rumman S, Mikell FL, Nallamothu N, Rangaswamy C. Stress cardiomyopathy: clinical and ventriculographic characteristics in 107 North American subjects. *Int J Cardiol*. 2010;141(3): 297-303.
16. Thiele H, Kappl MJ, Conradi S, Niebauer J, Hambrecht R, Schuler G. Reproducibility of chronic and acute infarct size measurement by delayed enhancement-magnetic resonance imaging. *J Am Coll Cardiol*. 2006; 47(8):1641-1645.
17. Friedrich MG, Sechtem U, Schulz-Menger J, et al; International Consensus Group on Cardiovascular Magnetic Resonance in Myocarditis. Cardiovascular magnetic resonance in myocarditis: a JACC white paper. *J Am Coll Cardiol*. 2009;53(17):1475-1487.
18. Van de Walle SO, Gevaert SA, Gheeraert PJ, De Pauw M, Gillebert TC. Transient stress-induced cardiomyopathy with an "inverted takotsubo" contractile pattern. *Mayo Clin Proc*. 2006;81(11):1499-1502.
19. Bondarenko O, Beek AM, Hofman MB, et al. Standardizing the definition of hyperenhancement in the quantitative assessment of infarct size and myocardial viability using delayed contrast-enhanced CMR. *J Cardiovasc Magn Reson*. 2005; 7(2):481-485.
20. Hurst RT, Askew JW, Reuss CS, et al. Transient midventricular ballooning syndrome: a new variant. *J Am Coll Cardiol*. 2006;48(3):579-583.
21. Yoshida T, Nishizawa T, Yajima K, et al. A rare case of tako-tsubo cardiomyopathy with variable forms of left ventricular dysfunction: a new entity. *Int J Cardiol*. 2009;134(2):e73-e75.
22. Rose JJ, Vanhecke TE, McCullough PA. Subarachnoid hemorrhage with neurocardiogenic stunning. *Rev Cardiovasc Med*. 2010;11(4):254-263.
23. Friedrich MG. Tissue characterization of acute myocardial infarction and myocarditis by cardiac magnetic resonance. *JACC Cardiovasc Imaging*. 2008; 1(5):652-662.
24. Rolf A, Nef HM, Möllmann H, et al. Immunohistological basis of the late gadolinium enhancement phenomenon in tako-tsubo cardiomyopathy. *Eur Heart J*. 2009;30(13):1635-1642.
25. Wu KC, Weiss RG, Thiemann DR, et al. Late gadolinium enhancement by cardiovascular magnetic resonance heralds an adverse prognosis in nonischemic cardiomyopathy. *J Am Coll Cardiol*. 2008;51(25): 2414-2421.
26. Heidary S, Patel H, Chung J, et al. Quantitative tissue characterization of infarct core and border zone in patients with ischemic cardiomyopathy by magnetic resonance is associated with future cardiovascular events. *J Am Coll Cardiol*. 2010;55(24):2762-2768.
27. Madhavan M, Borlaug BA, Lerman A, Rihal CS, Prasad A. Stress hormone and circulating biomarker profile of apical ballooning syndrome (takotsubo cardiomyopathy): insights into the clinical significance of B-type natriuretic peptide and troponin levels. *Heart*. 2009;95(17):1436-1441.
28. Haghi D, Roehm S, Hamm K, et al. Takotsubo cardiomyopathy is not due to plaque rupture: an intravascular ultrasound study. *Clin Cardiol*. 2010; 33(5):307-310.

 ©2011 American Medical Association. All rights reserved.

Downloaded From: http://jama.jamanetwork.com/ on 05/20/2013