Prevalence of Nonpolypoid (Flat and Depressed) Colorectal Neoplasms in Asymptomatic and Symptomatic Adults

Roy M. Soetikno, MD, MS
Tonya Kaltenbach, MD, MS
Robert V. Rouse, MD
Walter Park, MD
Anamika Maheshwari, MD
Tohru Sato, MD
Suzanne Matsui, MD
Shai Friedland, MD, MS

Context Colorectal cancer is the second leading cause of cancer death in the United States. Prevention has focused on the detection and removal of polypoid neoplasms. Data are limited on the significance of nonpolypoid colorectal neoplasms (NP-CRNs).

Objectives To determine the prevalence of NP-CRNs in a veterans hospital population and to characterize their association with colorectal cancer.

Design, Setting, and Patients Cross-sectional study at a veterans hospital in California with 1819 patients undergoing elective colonoscopy from July 2003 to June 2004.

Main Outcome Measures Endoscopic appearance, location, size, histology, and depth of invasion of neoplasms.

Results The overall prevalence of NP-CRNs was 9.35% (95% confidence interval [95% CI], 8.05%-10.78%; n=170). The prevalence of NP-CRNs in the subpopulations for screening, surveillance, and symptoms was 5.84% (95% CI, 4.13%-8.00%; n=36), 15.44% (95% CI, 12.76%-18.44%; n=101), and 6.01% (95% CI, 4.17%-8.34%; n=33), respectively. The overall prevalence of NP-CRNs with in situ or submucosal invasive carcinoma was 0.82% (95% CI, 0.46%-1.36%; n=15); in the screening population, the prevalence was 0.32% (95% CI, 0.04%-1.17%; n=2). Overall, NP-CRNs were more likely to contain carcinoma (odds ratio, 9.78; 95% CI, 3.93-24.4) than polypoid lesions, irrespective of the size. The positive size-adjusted association of NP-CRNs with in situ or submucosal invasive carcinoma was also observed in subpopulations for screening (odds ratio, 2.01; 95% CI, 0.27-15.3) and surveillance (odds ratio, 63.7; 95% CI, 9.41-431). The depressed type had the highest risk (33%). Nonpolypoid colorectal neoplasms containing carcinoma were smaller in diameter as compared with the polypoid ones (mean [SD] diameter, 15.9 [10.2] mm vs 19.2 [9.6] mm, respectively). The procedure times did not change appreciably as compared with historical controls.

Conclusion In this group of veteran patients, NP-CRNs were relatively common lesions diagnosed during routine colonoscopy and had a greater association with carcinoma compared with polypoid neoplasms, irrespective of size.

JAMA. 2008;299(9):1027-1035 www.jama.com

THE MAJORITY OF COLORECTAL cancer is believed to evolve through the growth of polypoid adenoma over time.[1] Current efforts to prevent colorectal cancer focus on the detection and removal of polypoid neoplasms.[2] Recent studies, however, have demonstrated that colorectal cancer can also arise from nonpolypoid colorectal neoplasms (NP-CRNs).[3-8] Nonpolypoid colorectal neoplasms are more difficult to detect by colonoscopy or computed tomography colonography[9] because the subtle findings can be difficult to distinguish from those of normal mucosa.[3,10] As compared with surrounding normal mucosa, NP-CRNs appear to be slightly elevated, completely flat, or slightly depressed. Although NP-CRNs are believed to exist primarily in Japan, recent studies have described their significance in other parts of the world.[8,11,12] In particular, depressed NP-CRNs, which have been described as the most difficult lesions to detect,[3] have the highest risk to be cancerous at the time of diagnosis.[4,5,10] Data on the potential importance of NP-CRNs as a precursor of colorectal cancer in the United States are currently limited.[12]

We hypothesized that NP-CRNs contribute importantly to the prevalence of colorectal cancer in the US population. We studied a large cohort of patients undergoing elective colonoscopy to estimate the prevalence of

For editorial comment see p 1068.

Author Affiliations: Veterans Affairs Palo Alto Health Care System, Palo Alto, California.
Corresponding Author: Roy Soetikno, MD, MS, Gastroenterology Section, Veterans Affairs Palo Alto Health Care System, 3801 Miranda Ave, GI-111, Palo Alto, CA 94304 (soetikno@earthlink.net).

©2008 American Medical Association. All rights reserved.

Downloaded From: http://jama.jamanetwork.com/ on 04/27/2015

NP-CRNs in a single Veterans Affairs population and characterize the association of NP-CRNs with colorectal cancer.

METHODS

We conducted this study during routine examinations in a large veterans hospital in California. The institutional review board at the Veterans Affairs Palo Alto Health Care System and Stanford University School of Medicine approved the study and waived the need for informed consent.

Preparation for the Study

The proficiency to diagnose NP-CRNs, which are difficult to distinguish from background normal mucosa,[3,4] required expertise that was not available in our unit. To develop the expertise, starting in early 1999 we developed a gastroenterology and pathology faculty exchange program with leading Japanese endoscopy centers, specifically with the National Cancer Center Hospital, Tokyo, Japan, and the National Cancer Center East, Kashiwa, Japan. For the purpose of self-study, we recorded uncompressed digital video of NP-CRN cases. Over time, these efforts allowed us to automatically seek characteristic findings of NP-CRNs, which include a slightly red appearance, altered or absent vascular network, friability, and wall deformity (FIGURE 1 and FIGURE 2).[3] The use of indigo carmine—sprayed to further characterize mucosa that may contain NP-CRNs—and the treatment of NP-CRNs using endoscopic mucosal resection (EMR) became routine practice in our unit starting in 2000[13,14] (see video at http://jama.ama-assn.org/cgi/content/full/299/9/1027/DC1).

Patient and Study Design

The study population consisted of consecutive adult patients who underwent outpatient colonoscopy from July 2003 to June 2004 by 4 board-certified gastroenterology faculties. Asymptomatic patients were those who underwent average risk-screening colonoscopy for colorectal cancer (the screening subpopulation) as well as patients who had surveillance colonoscopy because of personal or family history of colorectal neoplasm or cancer (the surveillance subpopulation). Symptomatic patients (the symptoms subpopulation) were those who had anemia, rectal bleeding, constipation, diarrhea, positive results from a fecal occult blood test, weight loss, abdominal pain, and inflammatory bowel disease that may be attributed to having colorectal neoplasms. Patients undergoing colonoscopy for emergency indications were excluded. Demographic information, which included self-classified race and ethnicity based on an investigator-defined checklist, was obtained from the study participants. Race and ethnicity were assessed because of the reported prevalence of NP-CRNs in the Asian population.

Colonoscopy

Patients were prescribed 4 L of polyethylene glycol solution and one 296-mL bottle of magnesium citrate or 90 mL of sodium phosphate solution to be taken orally the night prior to the procedure. Patients were permitted to eat low-residue foods on the day before colonoscopy. We used fentanyl or meperidine and midazolam for sedation.

We used commercially available high-resolution adult colonoscopes (CF-Q140L, CF-Q160L, or CF-Q160AL; Olympus America Inc, Allentown, Pennsylvania). We sprayed 10 to 25 mL of 0.1% to 0.4% diluted indigo carmine using a 60-mL syringe through the accessory channel when we suspected NP-CRNs. To prepare 25 mL of diluted indigo carmine, we mixed one 5-mL ampule of indigo carmine with 20 mL of water. We systematically in-

Figure 1. Depressed Type of Nonpolypoid Colorectal Neoplasm (NP-CRN)

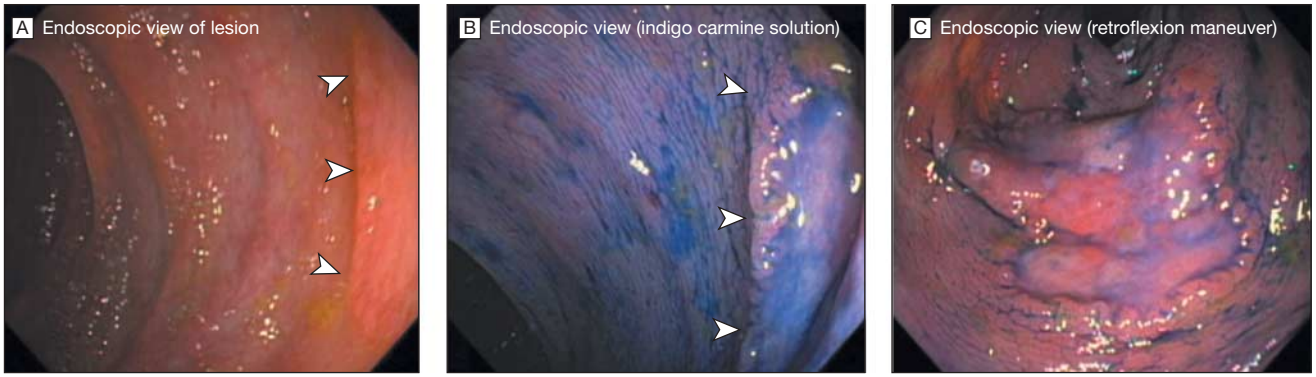

A, The lesion appeared as a deformed reddish patch of mucosa in the hepatic flexure (arrowheads). B, After spraying with diluted indigo carmine solution, the depressed lesion was more apparent, measuring about 4 cm in diameter. C, The lesion was best seen using a retroflexion maneuver. Endoscopic biopsy showed at least in situ carcinoma but could not exclude invasion. The patient underwent partial colectomy because a depressed colorectal neoplasm larger than 2 cm has more than 80% likelihood to contain submucosally invasive cancer, and complete endoscopic removal of such a depressed lesion is virtually impossible. (A video demonstrating the use of indigo carmine to locate NP-CRNs and the treatment of NP-CRNs using endoscopic mucosal resection is available at http://jama.ama-assn.org/cgi/content/full/299/9/1027/DC1.)

 ©2008 American Medical Association. All rights reserved.

Downloaded From: http://jama.jamanetwork.com/ on 04/27/2015

spected for lesions during withdrawal using a standard method.

We used a standard classification system described by the Japanese Society for Cancer of the Colon and Rectum (Figure 2).[3,15] The polypoid and nonpolypoid terminology describes superficial lesions—ie, lesions that involve the superficial layers (mucosa and submucosa) of the colorectal wall—whereas lesions that have penetrated into the muscularis propria or serosa are classified separately as advanced. The polypoid type consists of pedunculated or semipedunculated and sessile morphology. The nonpolypoid type comprises superficially elevated, completely flat, and depressed lesions. It is notable that the superficially elevated lesions are colloquially referred to as "flat" lesions because completely flat lesions are rare.[10]

Endoscopically, flat lesions are defined as those with a height of less than half of the lesion diameter, and depressed lesions are delineated by a base that is lower than the normal mucosa in height.[3] We calibrated our assessment of lesion size using an endoscopic measuring device (M2-3U; Olympus America Inc) or the span of an opened biopsy forceps. We recorded findings using database programs (EndoPro, Pentax Precision, Montvale, New Jersey; FoxPro, Microsoft Corp, Redmond, Washington; and FileMaker Pro, FileMaker Inc, Santa Clara, California).

Treatment of Lesions

We performed biopsy, polypectomy, or surgery as needed. We used the inject-and-cut EMR technique to resect NP-CRNs.[16,17] The technique involved inserting a needle beside the lesion and injecting a few milliliters of saline into the submucosa to lift it away from the muscularis propria. After the lesion was raised, we used a specialized mucosal resection snare (SD-210 or SD-230; Olympus America Inc) using a blend current. We repeated mucosal resection as necessary until the entire lesion was removed. We applied argon plasma coagulation (setting, 60 W at 1.2 L/min; ERBE USA, Atlanta, Georgia) to treat residual lesion.[18] In addition, to prevent immediate and delayed postpolypectomy bleeding, we used a detachable snare before resection of large pedunculated polyps[19] and clips to approximate the mucosal defect after resection of large (>1 cm) sessile or flat lesions.[18] We biopsied small polypoid lesions. We also biopsied lesions that did not rise with submucosal injection or had appearance of invasive cancer to obtain a diagnosis of neoplasms with or without invasive cancer and referred the patients to surgery.[20]

Follow-up Colonoscopy

We used the guidelines published by the US Multisociety Task Force on Colorectal Cancer in 2003,[21] and subsequently its revision in 2006,[22] to follow up patients who had 1 or more polypoid neoplastic lesions removed at colonoscopy. Patients who under-

Figure 2. Classification of Colorectal Lesions and Biopsy of Lesion With Submucosal Invasive Carcinoma

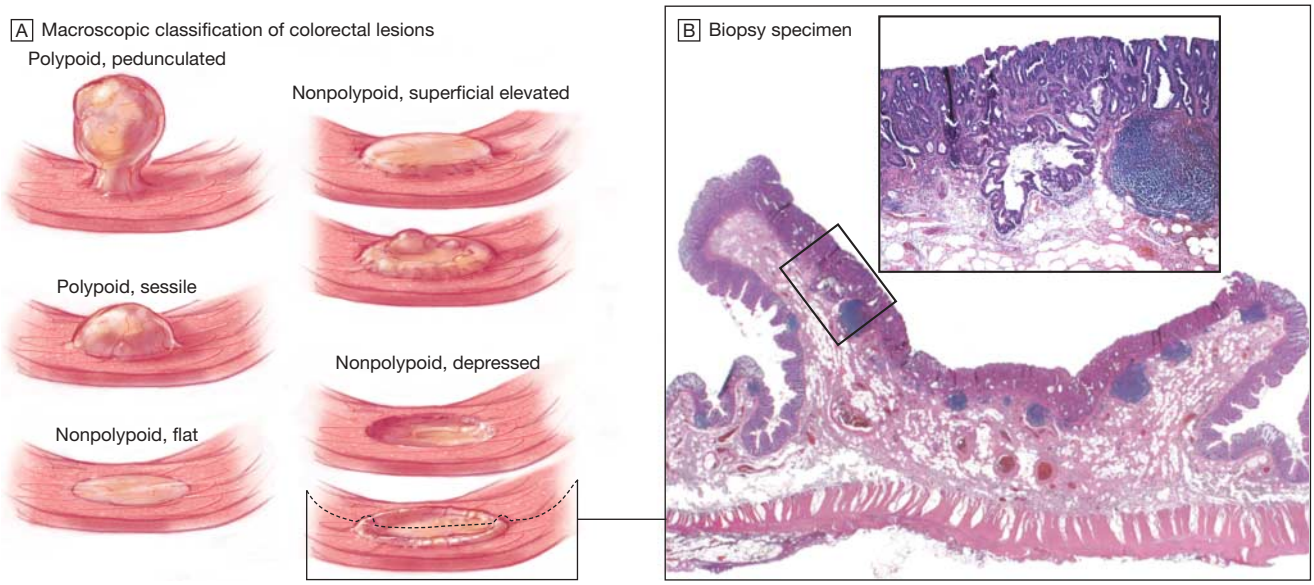

A, Macroscopic classification of superficial colorectal lesions (lesions that are limited to the mucosa and submucosa layers of the colorectal wall) used in this study.[3] The polypoid type consists of the pedunculated/semipedunculated and sessile morphology. The nonpolypoid type includes the superficial elevated, completely flat, and depressed morphology. Many endoscopists colloquially describe the superficial elevated lesions as flat lesions because the completely flat lesions are exceedingly rare in the colon. The term *flat* in this article refers to the superficially elevated lesions. B, The pathology showed submucosally invasive, moderately differentiated carcinoma without lymph node involvement (hematoxylin-eosin; original magnification ×10). Close-up view of 1 of the foci of invasion into the submucosa (inset) (hematoxylin-eosin; original magnification ×40).

©2008 American Medical Association. All rights reserved.

Downloaded From: http://jama.jamanetwork.com/ on 04/27/2015

Table 1. Baseline Patient Characteristics (N = 1819)

	No. (%)		
	Screening	Surveillance[a]	Symptomatic[b]
Total	616 (34)	654 (36)	549 (30)
Male	594 (96)	633 (97)	510 (93)
Race/ethnicity			
White	498 (81)	528 (81)	417 (76)
Hispanic	45 (7)	70 (11)	40 (7)
Black	48 (8)	36 (5)	62 (11)
Asian	25 (4)	20 (3)	30 (6)
Age, mean (SD), y	63 (9)	67 (10)	63 (13)

[a] Includes personal or family history of colorectal neoplasm or cancer.
[b] Includes indications of anemia, rectal bleeding, constipation, diarrhea, positive results from a fecal occult blood test, weight loss, abdominal pain, and inflammatory bowel disease.

went EMR had surveillance at 6 months to assess for lesion recurrence. The prior EMR site was located based on prior anatomic description and identified by a scar or india ink injection. Repeat EMR or biopsy was performed when there was residual lesion noted or there was any uncertainty about possible recurrence or residual tissue.

Duration and Complications of Colonoscopy

To determine whether the intervention had significantly lengthened the total procedure time, we compared the total procedure time with 100 randomly selected cases that were performed during the year prior to the study. Patients were followed up by telephone or in clinic after the procedure. All complications were recorded using a standardized form.

Pathology

We oriented the resected tissue after mucosal resection to obtain precise histopathologic diagnosis. The thin, curled-up specimens are flattened and fixed at the periphery using thin needles inserted into an underlying 4-mm–thick piece of balsa wood. After fixation, the specimen was sectioned serially at 2-mm intervals. We recorded data about the location, size, gross appearance, histology, microscopic depth of tumor invasion, neoplastic involvement of the margins, involvement of the lymphatics, and blood vessels.

We used histopathology classifications from the World Health Organization.[23] According to this classification, high-grade dysplasia (in situ carcinoma) is defined by considerable loss of nuclear polarity with irregular glandular architecture with no involvement beyond the muscularis mucosae. Submucosal invasive early colorectal cancer was defined as malignant lesions that invade the submucosal layer. The pathologists made the diagnoses of in situ or submucosal invasive carcinoma independently without written or oral communication from the endoscopists.

Statistical Analysis

We performed statistical analyses using Stata SE 9.1 for Apple computers (StataCorp, College Station, Texas). For univariate analysis, we used the *t* test and the Wilcoxon rank sum test or the Fisher exact test to compare continuous or categorical variables, respectively. We considered differences to be significant if the 2-tailed *P* value was less than .05.

We performed multivariate analyses of the association of early colorectal cancer in detected polyps with the shape of the lesion using a conditional random effects logistic regression, clustered by patient,[24] to obtain a more accurate variance and standard error. The use of this model allowed us to adjust for the potential correlation occurring because a patient can have more than 1 polyp. We performed diagnostics for assuring linearity of the predictor variables in a multipredictor model. We adjusted the model for lesion size because the risk that a neoplasm harbors carcinoma is known to increase with size. In addition, we explored endoscopist as a potential confounder.

RESULTS

Eighteen hundred nineteen patients underwent elective colonoscopy performed by 4 endoscopists during the 1-year study period from July 2003 to June 2004. Their demographic characteristics, according to procedure indications of screening, surveillance, or symptoms, are included in TABLE 1. The mean patient age (SD) was 64 (11) years. The patients were primarily men (95%; n=1737). The majority of the cohort (79%, n=1443) was white, and the minority (4%, n=75) was Asian. Asymptomatic patients accounted for the majority of procedure indications: screening (34%; n=616) and surveillance of patients with a personal or family history of colorectal neoplasm or cancer (36%; n=654). Colonoscopy in inflammatory bowel disease represented 37 patients (2%). The cecum was intubated in 1701 cases (94%).

Prevalence of Colorectal Neoplasms

We identified 764 patients (42% of the study cohort) as having at least 1 superficial colorectal neoplasm (FIGURE 3). The mean number of neoplasms per patient was 0.85 (range, 0-10). Nonpolypoid colorectal neoplasms were diagnosed in 170 patients (9.35%; 95% confidence interval [CI], 8.05%-10.78%). The prevalence of flat and depressed types of NP-CRNs was 8.58% (95% CI, 7.33%-9.96%; n=156) and 0.99% (95% CI, 0.59%-1.56%; n=18), respectively. Eighty-nine patients (5%; 95% CI, 3.94%-5.99%) had only neoplasms of nonpolypoid shape, whereas 81 patients (4.4%; 95% CI, 3.55%-5.50%) had both nonpolypoid and polypoid neoplasm and 594 patients (33%; 95% CI, 30.5%-34.9%) had only polypoid neoplasms. Thirteen patients (<1%; 95% CI, 0.38%-1.22%) had an advanced colorectal carcinoma, 312 patients (18%; 95% CI, 15.9%-19.5%) had

 ©2008 American Medical Association. All rights reserved.

Downloaded From: http://jama.jamanetwork.com/ on 04/27/2015

only nonneoplastic lesions, and 721 patients (40%; 95% CI, 37.4%-41.9%) had no lesion.

According to the procedure indication, the prevalence of NP-CRNs in screening, surveillance, and symptomatic adults is 5.84% (95% CI, 4.13%-8.00%; n=36), 15.44% (95% CI, 12.76%-18.44%; n=101), and 6.01% (95% CI, 4.17%-8.34%; n=33), respectively. Across the 3 cohorts of procedure indications, the likelihood of a nonpolypoid lesion containing neoplasms remained higher compared with polypoid lesions (TABLE 2): screening odds ratio [OR], 2.80 (95% CI, 1.31-5.98); surveillance OR, 3.30 (95% CI, 1.86-5.86); and symptomatic OR, 3.39 (95% CI, 1.46-7.88).

The prevalence of NP-CRNs containing in situ or submucosal invasive carcinoma was 0.82% (95% CI, 0.46%-1.36%; n=15). Nine patients (0.49%; 95% CI, 0.23%-0.94%) had a flat lesion and 6 patients (0.33%; 95% CI, 0.12%-0.72%) had a depressed lesion containing in situ or submucosal invasive carcinoma. The prevalence of NP-CRNs containing in situ or submucosal invasive carcinoma among patients undergoing screening for colorectal cancer was 0.32% (95% CI, 0.04%-1.17%; n=2, 1 flat and 1 depressed). Notably, almost half of the patients with NP-CRNs that contained in situ or submucosal invasive carcinoma had no other colorectal lesions other than carcinoma. Of these patients, 4 patients had a flat lesion with in situ carcinoma, 2 patients had a depressed lesion with in situ carcinoma, and 1 patient had a depressed submucosal invasive carcinoma.

Characteristics of Colorectal Neoplasms

TABLE 3 describes the nonneoplastic and neoplastic polyp characteristics according to their endoscopic morphology. Slightly more than half of superficial colorectal lesions detected were neoplastic. Of the neoplasms, 227 (14.8%) were nonpolypoid and the rest were polypoid. Two hundred nine of 227 NP-CRNs (92%; 95% CI, 87.8%-95.2%) were flat and 18 (8%; 95% CI, 4.77%-12.24%) were depressed.

Although nonpolypoid lesions accounted for only 15% of neoplasms, they contributed to 54% (95% CI, 35%-71%; n=15) of superficial carcinomas. Nonpolypoid morphology was strongly associated with findings of in situ or submucosal invasive carcinoma (OR, 11.1; 95% CI, 4.98-24.8). Adjusting for size, the association of a nonpolypoid lesion with in situ or submucosal invasive carcinoma continued to be significant compared with a polypoid shaped lesion in the entire study cohort (OR, 9.78; 95% CI, 3.93-24.4) as well as in the screening (OR, 2.01; 95% CI, 0.27-15.3) and surveillance (OR, 63.7; 95% CI, 9.41-431) subpopulations.

Categorizing morphology into flat, depressed, and polypoid, the size-adjusted multivariate model maintained an association of flat lesions with in situ or submucosal invasive carcinoma (OR, 5.18; 95% CI, 1.84-14.6). One-third (n=6) of the depressed lesions contained carcinoma. Depressed morphology also showed a positive OR (OR, 209; 95% CI, 44-1002), although the number of depressed colorectal neoplasms (n=18) was too few to statistically assess the magnitude of association of the depressed neoplastic lesions with in situ

Figure 3. Cohort Assembly of Study Patients

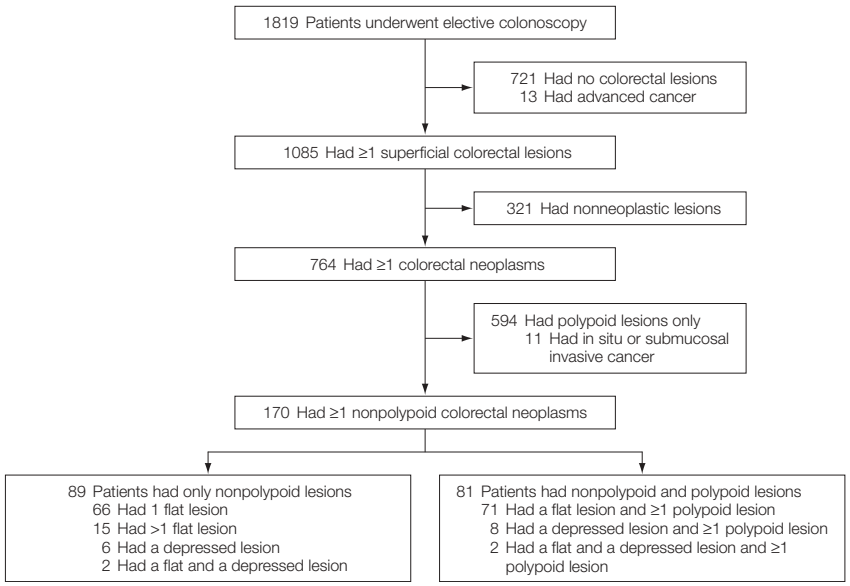

Table 2. Odds of Neoplasm Within Nonpolypoid Compared With Polypoid Colorectal Lesions Among Subpopulations Undergoing Colonoscopy[a]

Population Cohort	Neoplasm (n = 1535) Nonpolypoid	Neoplasm (n = 1535) Polypoid	Odds Ratio (95% CI)
All indications (N = 1819)	227	1308	3.25 (2.19-4.85)
Subpopulations			
Screening (n = 616)	52	475	2.80 (1.31-5.98)
Surveillance (n = 654)[b]	131	578	3.30 (1.86-5.86)
Symptomatic (n = 549)[c]	44	255	3.39 (1.46-7.88)

Abbreviation: CI, confidence interval.
[a] Univariate logistic regression was performed using conditional random effects assuming a model at a single level of clustering by patient.
[b] Includes personal or family history of colorectal neoplasm or cancer.
[c] Includes indications of anemia, rectal bleeding, constipation, diarrhea, positive results from a fecal occult blood test, weight loss, abdominal pain, and inflammatory bowel disease.

©2008 American Medical Association. All rights reserved.

Downloaded From: http://jama.jamanetwork.com/ on 04/27/2015

or submucosal invasive carcinoma. The 4 submucosal invasive and 11 carcinoma in situ nonpolypoid lesions were smaller in diameter as compared with the polypoid lesions with similar histology (mean [SD] diameter, 15.9 [10.2] mm vs 19.2 [9.6] mm, respectively). The depressed cancerous lesions were smallest in diameter (mean [SD], 9.7 [4.3] mm) (FIGURE 4).

Fifty-eight percent of NP-CRNs (n=131) were found in patients undergoing surveillance colonoscopy. To assess that the diagnosed NP-CRN lesions were de novo or were not detected previously, we individually reviewed the prior colonoscopy and pathology reports of the 95 patients diagnosed with NP-CRNs who had a history of polyps. In this subgroup of patients, 3 patients had flat adenomas identified near a scar, which is suggestive of residual adenoma from a previously resected sessile adenoma. Four patients had flat adenomas with a similar location as sessile lesions described in previous procedure reports. In these 7 patients, the possibility of NP-CRNs occurring because of incomplete treatment cannot be excluded. However, none of the lesions contained in situ or submucosal invasive carcinoma.

In addition, we explored the potential confounding effect of the endoscopist. Using χ^2, we determined that the estimated ORs for the association between neoplasm and nonpolypoid shape among endoscopists did not significantly vary, and the test of homogeneity of ORs across the strata of endoscopists was not significant at the 5% level. Visual inspection of the component ORs indicated that each endoscopist's findings represented positive associations between neoplasms and nonpolypoid shape, and the CIs overlapped. We did not adjust for endoscopist in the multivariate analysis.

Table 3. Characteristics of 2770 Superficial Colorectal Lesions, Neoplastic and Nonneoplastic, According to Endoscopic Morphology

	Neoplastic (n = 1535)			Nonneoplastic (n = 1235)	
	Nonpolypoid				
	Flat (n = 209)	Depressed (n = 18)	Polypoid (n = 1308)	Nonpolypoid Flat (n = 80)[a]	Polypoid (n = 1155)
Diameter, mean (range), mm	9 (3-40)	9 (2-20)	6 (1-70)	6 (1-25)	4 (1-50)
Indication, No. (%)					
Screening	48 (23)	4 (22)	475 (36)	27 (34)	452 (39)
Surveillance	119 (57)	12 (67)	578 (44)	38 (47)	457 (40)
Symptomatic	42 (20)	2 (11)	255 (20)	15 (19)	246 (21)
Race/ethnicity, No. (%)					
White	183 (88)	18 (100)	1034 (79)	68 (85)	936 (81)
Hispanic	9 (4)	0	121 (9)	8 (10)	88 (8)
Black	10 (5)	0	95 (7)	3 (4)	104 (9)
Asian	7 (3)	0	58 (5)	1 (1)	27 (2)
Location, No. (%)					
Cecum/ascending	78 (37)	3 (17)	454 (35)	15 (19)	167 (14)
Transverse	66 (32)	9 (50)	306 (23)	24 (30)	182 (16)
Descending/sigmoid	61 (29)	6 (33)	433 (33)	27 (34)	496 (43)
Rectum	4 (2)	0	115 (9)	14 (17)	310 (27)
Treatment, No. (%)					
Simple/hot biopsy	37 (17)	1 (5)	526 (40)	35 (44)	809 (70)
Polypectomy	14 (7)	0	308 (23)	5 (6)	175 (15)
Mucosectomy	152 (73)	12 (67)	466 (36)	40 (50)	171 (15)
Surgery	6 (3)	5 (28)	8 (<1)	0	0
Pathology, No. (%)					
Invasive cancer	2 (1)	2 (11)	8 (0.5)	0	0
Carcinoma in situ	7 (3.5)	4 (22)	5 (0.5)	0	0
Villous adenoma	5 (2.5)	0	33 (3)	0	0
Tubular adenoma	195 (93)	12 (67)	1262 (96)	0	0
Hyperplastic	0	0	0	53 (66)	680 (59)
No specific abnormality	0	0	0	22 (28)	426 (37)
Lost specimen	0	0	0	5 (6)	49 (4)

[a] There was no nonneoplastic pathology found in depressed lesions.

Treatment

The majority (72%; n=164) of the 227 NP-CRNs were managed with colonoscopy using EMR. Of the 200 flat lesions containing tubular or villous adenoma, 148 (74%) were treated with EMR, 38 (19%) with cold or hot biopsy, 14 (7%) with snare polypectomy, and 1 (less than 1%) with surgery. The 7 flat lesions with carcinoma in situ were managed using either EMR (57%; n=4) or surgery (43%; n=3), and both of the flat lesions with invasive cancer were managed with surgery. Of the 12 depressed lesions that contained tubular adenoma, 9 (75%) were resected with EMR, 1 (8%) with hot biopsy, and 2 (17%) with surgery. Treatment choice (EMR or surgery) was distributed equally in the 6 depressed lesions that contained in situ or invasive cancer.

Findings at Follow-up Colonoscopy

Follow-up colonoscopy data of the 580 patients who were recommended to have follow-up at 3 years or less are available for 393 patients (68%). Of the remaining, 153 (26%) did not adhere to the recommendation, 24 (4%) were deceased, and 10 (2%) were lost to follow-up. No patient died from newly diagnosed colorectal cancer during the follow-up. Follow-up colonoscopy results according to the most advanced finding at the index study colonoscopy are summarized in TABLE 4. On follow-up, we found 13 advanced colorectal neoplasia: 1 flat T1N0 rectal carcinoma and 1 villous and 11 tubular adenomas 10 mm or larger. The morphology of the 12 adenomatous lesions include 5 flat and 7 polypoid with a mean (SD) size of 15.4 (7.6) mm (range, 10-30 mm).

 ©2008 American Medical Association. All rights reserved.

Downloaded From: http://jama.jamanetwork.com/ on 04/27/2015

Duration and Complications of Colonoscopy

The average procedure time, including using indigo carmine spray, was 33 minutes (range, 7-77 minutes). In comparison, the average procedure time of colonoscopy prior to the introduction of our efforts to diagnose NP-CRNs was 34.5 minutes (range, 9-98 minutes) (P=.51). The mean (SD) patient age (65 [11] years), race distribution (white, 84%; Hispanic, 4%; black, 8%; and Asian, 4%), and procedure indications (screening, 34%; surveillance, 45%; symptomatic, 25%) of the comparison group were similar.

Six patients had complications: 5 with bleeding per rectum due to mucosal resection (3 patients) or hot forceps biopsy (2 patients) and 1 with significant colonic distention. These patients presented between 1 and 9 days (average, 6 days) after the colonoscopy. Two of the patients with bleeding had repeat colonoscopy for hemostasis using placement of endoscopic clips; 1 required 2 units of blood transfusion. The other 3 patients had self-limited bleeding that was treated with supportive care. The patient with colonic distention was treated with bowel rest and fluids. The average hospitalization for these 6 patients was 1.5 days (range, 0-3 days). There was no associated mortality.

COMMENT

Our study provides supporting evidence that NP-CRNs are a relatively common finding among white patients in a single Veterans Affairs population, with a prevalence of 9.3%.

The prevalence in patients undergoing colonoscopy for screening, surveillance, and symptoms are 5.8%, 15.4%, and 6.0%, respectively. The nonpolypoid morphology is independently associated with a lesion containing in situ or submucosal invasive carcinoma. We found that more than half of the in situ or submucosal invasive carcinomas (n=15) were diagnosed among NP-CRN lesions while NP-CRNs contributed to approximately 15% of neoplasms overall. In this series of patients treated at the Veterans Affairs Palo Alto Health Care System, the depressed type of NP-CRN, which is the most difficult to detect during colonoscopy, had the highest likelihood of containing in situ or submucosal invasive carcinoma.

The OR that NP-CRNs contained in situ and submucosal invasive carcinoma was approximately 10 times higher than polypoid lesions, irrespective of its size, although the wide CI (5-25) precluded drawing a strong conclusion. The improved detection of NP-CRNs (and polypoid ones) may lead to our ability to increase the efficacy and effectiveness of colonoscopy to prevent the development of colorectal cancer. Between 0.3% and 0.9% of patients develop interval cancer, which is advanced cancer, within 3 years after having colonoscopy with adenomas removed.[25] The reasons may include missed lesions, incomplete removal of adenomas, and new fast-growing lesions. It is possible that NP-CRNs containing carcinoma, similar to the ones shown in this study, contribute to the pool of missed lesions. The higher propensity for the NP-CRNs to contain carcinoma at the time of detection and their similar prevalence to that of interval carcinoma provides support for this possible contribution. Observational studies have shown that when left untreated, NP-CRNs with carcinomas can progress to advanced cancer within a similar time frame.[10,26,27] Once the NP-CRNs become advanced cancer, their appearance is indistinguishable from

Figure 4. Distribution of Size of Neoplastic Colorectal Lesions According to Morphology and Pathology

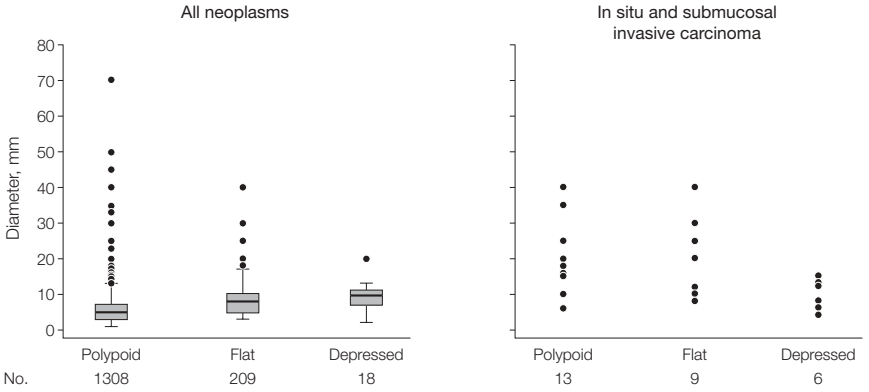

The height of the box displays interquartile range (IQR) with the 25th and 75th percentiles representing the lower and upper edges of the box, respectively. The middle horizontal line across the box is the median. Error bars extend from the box to show the minimum and maximum data points ("whiskers"). The lower whisker represents the 25th percentile minus 1.5 times IQR and the upper whisker represents the 75th percentile plus 1.5 times IQR. Values outside of the whiskers are defined as outliers.[24]

Table 4. Advanced Neoplasia at Follow-up Colonoscopy at 3 Years or Less

	Follow-up Colonoscopy Interval ≤3 y, No. (%)		
Index Cohort (N = 1819)	Colonoscopy Recommended (n = 580)	Colonoscopy Performed (n = 393)	Advanced Neoplasm (n = 13)
No neoplasia (n = 1042)	212	146 (69)	4 (2.7)
Neoplasia (n = 764)	362	243 (67)	9 (3.7)
Adenoma <10 mm (n = 514)	189	130 (69)	1 (0.8)
Adenoma ≥10 mm (n = 192)	138	87 (63)	8 (9.2)
Villous adenoma (n = 32)	20	13 (65)	0
In situ or submucosal invasive carcinoma (n = 26)	15	13 (87)	0
Advanced cancer (n = 13)	6	4 (67)	0

©2008 American Medical Association. All rights reserved.

Downloaded From: http://jama.jamanetwork.com/ on 04/27/2015

those that originated from the polypoid ones.[4]

Follow-up colonoscopy data within 3 years of patient enrollment are available. Our follow-up data are best compared with the results of Veterans Affairs Cooperative Study No. 380 because of similar patient populations.[28] Other published longitudinal studies were performed in the 1980s, and the optics of the colonoscopes have since improved.[29,30] We found 13 of 393 patients to have advanced neoplasia, all of which were flat or sessile adenomas 10 mm or larger except for 1 T1 carcinoma. The low rates of advanced neoplasia (3.3%; 95% CI, 1.77%-5.59%) and interval cancer (0.25%; 95% CI, 0.006%-1.41%) found in the follow-up colonoscopy differ from those found in the cooperative study. In the cooperative study, during a similar follow-up period, 32 of 557 patients (7.5%) were diagnosed with advanced neoplasia. In these patients, 15 interval carcinomas were found (2 metastatic, 4 advanced, 2 submucosal invasive, and 6 in situ), approximately 40% of which could have been explained from incompletely removed lesions.[28] It is possible that some of the remaining in situ or invasive carcinoma arose from undetected NP-CRNs. Other advanced neoplasia might result from progression of adenomatous nonpolypoid and polypoid lesions. In our study, we also diagnosed flat and sessile adenomas that were likely to have been missed during the initial colonoscopy because of incomplete bowel preparation, their shape being nonpolypoid, or their location behind folds or in the rectum.

The current study represents the largest cohort of patients in which NP-CRNs have been formally evaluated in a non-Asian population, and its findings support the results of published existing data.[5,7,8,12] Our cross-sectional study may, however, have limitations in generalizability and long-term follow-up. The prevalence of NP-CRNs reported in our study is notably similar to that reported in colonoscopy studies from other centers. The proportion of NP-CRNs among superficial neoplasms was 14.8%, which is within the range of prior reports.[5,8] Results may vary due to the mixed population as well as the fact that smaller lesions are more difficult to classify strictly as flat or sessile. Our prevalence and proportion of NP-CRN rates appear higher than those reported in a computed tomography colonography study in the United States. Pickhardt and colleagues[31] found the proportion of flat neoplasms larger than 6 mm to be 4.9%. We found it to be approximately 25%. The reason for the discrepancy is unclear, but several studies demonstrate that NP-CRNs are difficult to detect using computed tomography colonography.[9,32,33]

In conclusion, in this population of patients at a single Veterans Affairs hospital, NP-CRNs were a relatively common finding during colonoscopy. They were more likely to contain carcinoma compared with polypoid neoplasms, independent of lesion size. Recent studies have pointed out differences in the genetic mechanisms underlying nonpolypoid and polypoid colorectal neoplasms.[34,35] Future studies on NP-CRNs should further evaluate whether the diagnosis and removal of NP-CRNs has any effect on the prevention and mortality of colorectal cancer and particularly focus on their genetic and protein abnormalities.

Author Contributions: Dr Soetikno had full access to all of the data in the study and takes responsibility for the integrity of the data and the accuracy of the data analysis.
Study concept and design: Soetikno.
Acquisition of data: Soetikno, Kaltenbach, Rouse, Park, Maheshwari, Sato, Matsui, Friedland.
Analysis and interpretation of data: Soetikno, Kaltenbach, Rouse, Park, Maheshwari, Matsui.
Drafting of the manuscript: Soetikno, Kaltenbach.
Critical revision of the manuscript for important intellectual content: Soetikno, Kaltenbach, Rouse, Park, Maheshwari, Sato, Matsui, Friedland.
Statistical analysis: Soetikno, Kaltenbach, Park, Maheshwari.
Obtained funding: Soetikno.
Administrative, technical, or material support: Soetikno, Kaltenbach, Rouse, Park, Maheshwari, Sato, Matsui, Friedland.
Study supervision: Soetikno, Matsui.
Financial Disclosures: None reported.
Funding/Support: The Palo Alto Institute provided funding for the study for Research and Education, a nonprofit organization.
Role of the Sponsor: The Palo Alto Institute had no role in the design and conduct of the study; in the collection, analysis, and interpretation of the data; or in the preparation, review, or approval of the manuscript.
Additional Information: A video demonstrating the use of indigo carmine to locate NP-CRNs and the treatment of NP-CRNs using endoscopic mucosal resection is available online at http://jama.ama-assn.org/cgi/content/full/299/9/1027/DC1.
Additional Contributions: We thank the nurses and staff of the Veterans Affairs Palo Alto Health Care System endoscopy and pathology units for their assistance. We would also like to express our sincere appreciation to our Japanese endoscopy and pathology colleagues, in particular Shin-ei Kudo, MD, PhD, Showa University, Yokohama, Japan; Takahiro Fujii, MD, PhD, National Cancer Center Hospital, Tokyo, Japan; and Yasushi Sano, MD, PhD, National Cancer Center East, Kashiwa, Japan, who contributed significant knowledge and technical assistance without receiving compensation from this study.

REFERENCES

1. Vogelstein B, Fearon ER, Hamilton SR, et al. Genetic alterations during colorectal-tumor development. *N Engl J Med*. 1988;319(9):525-532.
2. Winawer SJ, Zauber AG, Ho MN, et al. Prevention of colorectal cancer by colonoscopic polypectomy: the National Polyp Study Workgroup. *N Engl J Med*. 1993;329(27):1977-1981.
3. Kudo S. *Early Colorectal Cancer*. Tokyo, Japan: Igaku-Shoin; 1996.
4. Kudo S, Kashida H, Tamura T, et al. Colonoscopic diagnosis and management of nonpolypoid early colorectal cancer. *World J Surg*. 2000;24(9):1081-1090.
5. Rembacken BJ, Fujii T, Cairns A, et al. Flat and depressed colonic neoplasms: a prospective study of 1000 colonoscopies in the UK. *Lancet*. 2000;355(9211):1211-1214.
6. Hurlstone DP, Cross SS, Adam I, et al. A prospective clinicopathological and endoscopic evaluation of flat and depressed colorectal lesions in the United Kingdom. *Am J Gastroenterol*. 2003;98(11):2543-2549.
7. Jaramillo E, Watanabe M, Slezak P, Rubio C. Flat neoplastic lesions of the colon and rectum detected by high-resolution video endoscopy and chromoscopy. *Gastrointest Endosc*. 1995;42(2):114-122.
8. Tsuda S, Veress B, Toth E, Fork FT. Flat and depressed colorectal tumours in a southern Swedish population: a prospective chromoendoscopic and histopathological study. *Gut*. 2002;51(4):550-555.
9. Fidler JL, Johnson CD, MacCarty RL, Welch TJ, Hara AK, Harmsen WS. Detection of flat lesions in the colon with CT colonography. *Abdom Imaging*. 2002;27(3):292-300.
10. Soetikno R, Friedland S, Kaltenbach T, Chayama K, Tanaka S. Nonpolypoid (flat and depressed) colorectal neoplasms. *Gastroenterology*. 2006;130(2):566-576.
11. Fujii T, Rembacken BJ, Dixon MF, Yoshida S, Axon AT. Flat adenomas in the United Kingdom: are treatable cancers being missed? *Endoscopy*. 1998;30(5):437-443.
12. Saitoh Y, Waxman I, West AB, et al. Prevalence and distinctive biologic features of flat colorectal adenomas in a North American population. *Gastroenterology*. 2001;120(7):1657-1665.
13. Fujii T, Hasegawa RT, Saitoh Y, et al. Chromoscopy during colonoscopy. *Endoscopy*. 2001;33(12):1036-1041.
14. Soetikno RM, Fujii T, Friedland S, Barro J, Matsui S, Rouse RV. *Diagnosis of Flat and Depressed Colorectal Neoplasms: an Educational DVD*. Chicago, IL: American Society for Gastrointestinal Endoscopy; 2004.
15. Yasutomi M, Baba S, Hojo K, et al. *Japanese Classification of Colorectal Carcinoma*. Tokyo, Japan: Kanehara & Co Ltd; 1997.

 ©2008 American Medical Association. All rights reserved.

Downloaded From: http://jama.jamanetwork.com/ on 04/27/2015

16. Kudo S. Endoscopic mucosal resection of flat and depressed types of early colorectal cancer. *Endoscopy*. 1993;25(7):455-461.
17. Rembacken BJ, Gotoda T, Fujii T, Axon AT. Endoscopic mucosal resection. *Endoscopy*. 2001;33(8):709-718.
18. Kaltenbach T, Friedland S, Maheshwari A, et al. Short- and long-term outcomes of standardized EMR of nonpolypoid (flat and depressed) colorectal lesions > or=1 cm (with video). *Gastrointest Endosc*. 2007;65(6):857-865.
19. Iishi H, Tatsuta M, Narahara H, Iseki K, Sakai N. Endoscopic resection of large pedunculated colorectal polyps using a detachable snare. *Gastrointest Endosc*. 1996;44(5):594-597.
20. Saitoh Y, Obara T, Watari J, et al. Invasion depth diagnosis of depressed type early colorectal cancers by combined use of videoendoscopy and chromoendoscopy. *Gastrointest Endosc*. 1998;48(4):362-370.
21. Winawer S, Fletcher R, Rex D, et al; Gastrointestinal Consortium Panel. Colorectal cancer screening and surveillance: clinical guidelines and rationale: update based on new evidence. *Gastroenterology*. 2003;124(2):544-560.
22. Rex DK, Kahi CJ, Levin B, et al; American Cancer Society; US Multisociety Task Force on Colorectal Cancer. Guidelines for colonoscopy surveillance after cancer resection: a consensus update by the American Cancer Society and the US Multisociety Task Force on Colorectal Cancer. *Gastroenterology*. 2006;130(6):1865-1871.
23. Hamilton SR, Aaltonen LA. *World Health Organization Classification of Tumours: Pathology and Genetics: Tumours of the Digestive System.* Lyon, France: IARC Press; 2000.
24. Vittinghoff E, Glidden DV, Shiboski SC, McCulloch CE. *Regression Methods in Biostatistics: Linear, Logistic, Survival and Repeated Measures Models.* New York, NY: Springer; 2005.
25. Lieberman D. A call to action: measuring the quality of colonoscopy. *N Engl J Med*. 2006;355(24):2588-2589.
26. Matsui T, Tsuda S, Iwashita A, et al. Retrospective endoscopic study of developmental and configurational changes of early colorectal cancer: eight cases and a review of the literature. *Gastroenterological Endoscopy*. 2005;47(2):227-237.
27. Matsui T, Yao T, Iwashita A. Natural history of early colorectal cancer. *World J Surg*. 2000;24(9):1022-1028.
28. Lieberman DA, Weiss DG, Harford WV, et al. Five-year colon surveillance after screening colonoscopy. *Gastroenterology*. 2007;133(4):1077-1085.
29. Kronborg O, Jorgensen OD, Fenger C, Rasmussen M. Three randomized long-term surveillance trials in patients with sporadic colorectal adenomas. *Scand J Gastroenterol*. 2006;41(6):737-743.
30. O'Brien MJ, Winawer SJ, Zauber AG, et al. Flat adenomas in the National Polyp Study: is there increased risk for high-grade dysplasia initially or during surveillance? *Clin Gastroenterol Hepatol*. 2004;2(10):905-911.
31. Pickhardt PJ, Nugent PA, Choi JR, Schindler WR. Flat colorectal lesions in asymptomatic adults: implications for screening with CT virtual colonoscopy. *AJR Am J Roentgenol*. 2004;183(5):1343-1347.
32. Park SH, Lee SS, Choi EK, et al. Flat colorectal neoplasms: definition, importance, and visualization on CT colonography. *AJR Am J Roentgenol*. 2007;188(4):953-959.
33. Van Gelder RE, Nio CY, Florie J, et al. Computed tomographic colonography compared with colonoscopy in patients at increased risk for colorectal cancer. *Gastroenterology*. 2004;127(1):41-48.
34. Nosho K, Yamamoto H, Adachi Y, Endo T, Hinoda Y, Imai K. Gene expression profiling of colorectal adenomas and early invasive carcinomas by cDNA array analysis. *Br J Cancer*. 2005;92(7):1193-1200.
35. Hiraoka S, Kato J, Tatsukawa M, et al. Laterally spreading type of colorectal adenoma exhibits a unique methylation phenotype and K-ras mutations. *Gastroenterology*. 2006;131(2):379-389.

It is vain to say human beings ought to be satisfied with tranquility: they must have action; and they will make it if they cannot find it.
—Charlotte Brontë (1816-1855)

©2008 American Medical Association. All rights reserved.

Downloaded From: http://jama.jamanetwork.com/ on 04/27/2015